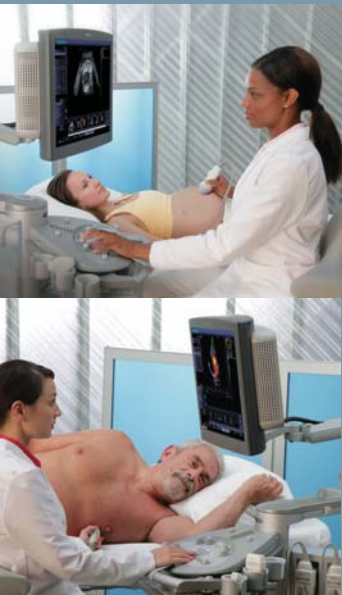



The new ACUSON Antares.
Do it all.

www.siemens.com.au/medical

Proven Outcomes in Ultrasound

In creating the new ACUSON Antares™ ultrasound system, premium edition, we broadened our discussion with ultrasound clinicians world-wide, investigating your latest, most pressing clinical issues. In the end, we gave you just what you asked for: a system designed around you, our most important customer, enabling you to excel at virtually any ultrasound challenge.

Across the full range of ultrasound examinations, including cardiac imaging, the new Antares system delivers the impressive combination of superior image quality, operator-friendly ErgoDynamic™ imaging system design, applications versatility, and the latest advancements in clinical workflow. So no matter what diagnostic challenge walks in the door, you'll know you already have the answer.

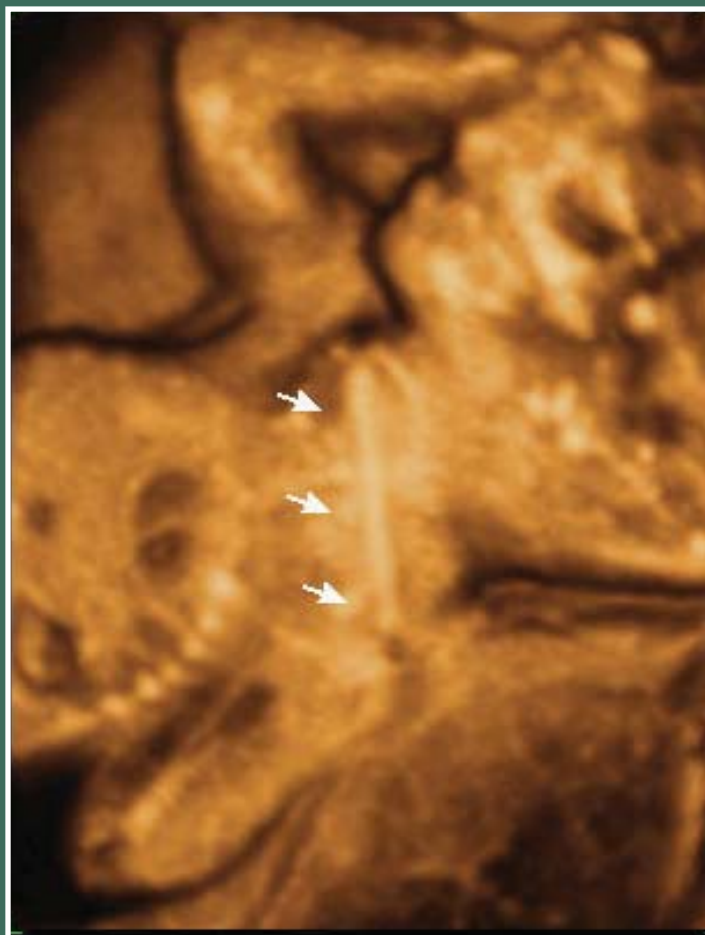
Australia: 1800 227 587

New Zealand: 0800 251 111

SIEMENS
medical

Ultrasound Bulletin

Journal of the Australasian Society for Ultrasound in Medicine



Australasian Society for Ultrasound in Medicine

Multidisciplinary Ultrasound Workshop

26 – 30 March 2008
Sydney, Australia

Convenors

Dr Glenn McNally
Obstetrics & Gynaecology
and Point of Care Course

Dr Susan Campbell
Westerway
General

Mrs Jenifer Kidd
Vascular

Associated Meetings

**DDU Technical
Seminars**
26 – 27 March 2008

**DMU Preparation
Courses**
26 – 30 March 2008

**Nuchal Translucency
Course**
27 March 2008



Promoting Excellence
in Ultrasound

ASUM Head Office

PO Box 943
Crows Nest NSW 1585
Sydney, Australia
Telephone: +61 2 9438 2078
Facsimile: +61 2 9438 3686
Email: asum@asum.com.au
Website: www.asum.com.au

Meeting Office

ICMS Pty Ltd
Locked Bag Q4002
QVB Post Office
Sydney NSW 1230
Australia
Telephone: +61 2 9290 3366
Facsimile: +61 2 9290 2444

✓ 18 reasons (at least) why you should join ASUM

ASUM is a unique professional society dedicated to excellence in ultrasound and the professionals who work in this vital and constantly evolving medical specialty.

✓ 1 Professional qualifications

Diploma in Medical Ultrasound (DMU)
Diploma in Diagnostic Ultrasound (DDU)
Certificate in Clinician Performed Ultrasound (CCPU)

✓ 2 Ultrasound training

The new ASUM College of Ultrasound accepts its first students in 2006

✓ 3 Online education

Free online physics education for DMU and DDU candidates

✓ 4 Online clinical handbook

A reference collection of images, cases and differential diagnoses

✓ 5 Educational resources

Extensive library of ultrasound videos, CDs and DVDs

✓ 6 Policies and statements

Guidelines, updates and worksheets used by policy makers

✓ 7 MOSIPP

Recording of CPD/CME points

✓ 8 Professional advancement

Speaking opportunities at meetings in Australia, New Zealand and Asia

✓ 9 Published author

Publish your research in the ASUM Ultrasound Bulletin

✓ 10 Research Grants

ASUM supports research which extends knowledge of clinical ultrasound

✓ 11 Service to medical ultrasound

ASUM welcomes ultrasound professionals to its Council and committees

✓ 12 Attend ASUM meetings at reduced rates

Members enjoy special registration fee discounts for the Annual Scientific Meeting and Multidisciplinary Workshops

✓ 13 Professional, quality networking

Connect with your colleagues and ultrasound systems suppliers at meetings and workshops and through high quality networks

✓ 14 Free website employment advertising

Advertising for staff on the ASUM website is free to ASUM members

✓ 15 Ultrasound Bulletin delivered to your door

The quarterly ASUM Ultrasound Bulletin is highly regarded both for its medical ultrasound articles and professional news content

✓ 16 Professional indemnity insurance

Peace of mind for sonographer members for a modest annual premium

✓ 17 Special home loan rates from AMP

AMP is one of Australia's biggest home lenders. ASUM members qualify for special home loan rates

✓ 18 Drive for less with Hertz

ASUM Members qualify for discounted Hertz car hire rates

Australasian Society for Ultrasound in Medicine

Level 2, 511 Pacific Highway
St Leonards NSW 2065 Australia
tel +61 2 9958 7655 fax +61 2 9958 8002
email asum@asum.com.au



Australasian
Society for
Ultrasound in
Medicine

President

Dr Matthew Andrews

Honorary Secretary

Mrs Roslyn Savage

Honorary Treasurer

Dr Andrew Ngu

Chief Executive Officer

Dr Caroline Hong

ULTRASOUND BULLETIN

Official publication of
the Australasian Society
for Ultrasound in Medicine

Published quarterly

ISSN 1441-6891

Indexed by the Sociedad Iberoamericana de
Informacion Cientifican (SIIC) Databases

Editor

Prof Ron Benzie

University of Sydney, Division of Women's and
Children's Health Nepean Hospital
Penrith NSW

Co-Editor

Mr Keith Henderson
ASUM Education Manager

Editorial Coordinator

Mr James Hamilton
ASUM Education Officer

Assistant Editors

Ms Kaye Griffiths AM
ANZAC Institute CRGH Concord NSW

Ms Janine Horton
Nanosonics NSW

Ms Louise Lee
Sessional Sonographer

Mr Adam Lunghi
Echo Services WA

Assoc Prof Amarendra Trivedi
Peninsula Health Vic

Ms Jacqui Robinson
Liverpool Hospital NSW

Editorial contributions

Original research, case reports, quiz cases,
short articles, meeting reports and calen-
dar information are invited and should be
addressed to The Editor at the address below

Membership and general enquiries

to ASUM at the address below

Published on behalf of ASUM

by Minnis Communications

Bill Minnis Director
4/16 Maple Grove
Toorak Melbourne Victoria 3142 Australia
tel +61 3 9824 5241 fax +61 3 9824 5247
email minnis@minniscomms.com.au

Disclaimer

Unless specifically indicated, opinions
expressed should not be taken as those of
the Australasian Society for Ultrasound in
Medicine or of Minnis Communications

AUSTRALASIAN SOCIETY FOR ULTRASOUND IN MEDICINE

ABN 64 001 679 161

Level 2, 511 Pacific Highway St Leonards
Sydney NSW 2065 Australia

tel +61 2 9438 2078 fax +61 2 9438 3686
email asum@asum.com.au

website: <http://www.asum.com.au>



THE EXECUTIVE

President's message	5	ASUM President's speech at the opening of ASUM's new office plus pictures
CEO's message	11	CEO on the Society's latest activities
Editor's column	15	The Editor wants your material for publication

DIAGNOSTIC ULTRASOUND

Detecting fetal growth restriction: can we improve on ultrasound techniques?	16	This opinion piece from Max Mongelli questions current clinical screening methods for intra-uterine growth restriction and small-for-gestational-age fetuses and whether antenatal detection actually improves outcomes
A new method for ultrasound evaluation of the iliopsoas tendon insertion	19	The iliopsoas tendon is one of the most difficult to visualise sonographically. In this article Stephen Bird shares his approach to visualising the tendon
Assessing the variable of patient positioning when examining the lower limb veins for reflux using spectral and colour Doppler ultrasound	22	The object of this study was to determine the influence of patient position (erect and semi-recumbent) on outcome diagnosis of venous reflux using spectral and colour Doppler ultrasound
Sonography – the emergence of a profession	29	This paper discusses the history of ultrasound, the emergence of sonography as a profession and the title 'sonographer' as a professional role. The education of sonographers in Australia is also explored
The prenatal imaging of thanatophoric skeletal dysplasia: a case review	35	Thanatophoric dysplasia is a fatal skeletal dysplasia. This article discusses its diagnosis in a twenty-six-year-old patient's fetus
Scanning the journals	38	The Gleaner distills the latest and best papers on ultrasound published worldwide
POLICIES AND STATEMENTS	39	Policies and Statements reaffirmed, revised and adopted by Council
C2 The Role of the Sonographer	39	
B7 Guidelines for the Operation of Vascular Ultrasound Practices July 2007	40	

REPORTS

Adjudication of prizes at 2007 AGM	41	Put yourself in line for prizes at this year's AGM
Prof Fung Yee Chan 1955–2007	43	Farewell to a friend and colleague
Prestigious award for ASUM member	44	Kathryn Busch wins prize at the Society of Vascular Sonographers Conference in the USA
Scanning at Tu Du Hospital Saigon	45	ASUM Asia-link at work in Vietnam

EDUCATION

2007 DDU Report	47	The DDU continues to attract candidates
Why do we need a CCPU?	48	The CCPU will credential a wider range of medical areas
ASUM CCPU Report	49	62 doctors are enrolled in the CCPU program
New intake at Vision College	49	ASUM's presence in Malaysia continues
WA CPD Meeting	49	Another lively meeting in the west

NOTICES

Corporate members	50
New members	50
Calendar	51
Guidelines for authors	52

WFUMB 2009

Sydney
Australia

12th Congress of the
World Federation
for Ultrasound in
Medicine and Biology
August 30 – September 3, 2009



Program Cairns Annual

Thursday, 13th September 2007

Skills Development Workshop

	GE Healthcare Room	Toshiba Room	Philips Room	Siemens Medical Room
9.00 am–9.50 am	Breast Ultrasound – Mrs Lynette Hassall	The 18 Week Scan – Mrs Shirley Comminos	Vascular Scanning: the Challenges – Dr Joseph Polak	Ultrasound of the Wrist and Hands – Dr Carlo Martinoli
10.00 am–10.40 am	Ultrasound of Mammary Implants – Dr Tom Stavros	Fetal Echocardiography – Dr Alison Lee-Tannock	Chronic Venous Insufficiency Scanning – Ms Deb Coghlan	11–12 Week Scan – Dr David Nyberg
10.40 am–11.10 am Morning Tea				
11.10 am–12.00 pm	Breast Ultrasound – Mrs Lynette Hassall	Breast Cytology and Basic Breast Pathology – Dr Susane Fraser	Unusual Carotid Pathology – Mrs Yvonne Butcher	Tertiary Scanning – Dr David Nyberg
12.00 pm–1.00 pm Lunch				
1.00 pm–1.50 pm	Dynamic Ultrasound of Groin Hernias – Dr Tom Stavros	Fetal Echocardiography – Dr Alison Lee-Tannock	Arm Arteries – Ms Deb Coghlan	11–12 Week Scan – Dr David Nyberg
2.00 pm–2.40 pm	Dynamic Ultrasound of Groin Hernias – Dr Tom Stavros	Fetal Echocardiography – Dr Alison Lee-Tannock	Arm Veins – Ms Deb Coghlan	Ultrasound of the Wrist and Hands – Dr Carlo Martinoli
2.40 pm–3.10 pm Afternoon Tea				
3.10 pm–3.50 pm	Ultrasound of the Appendix – Mr Richard Allan	Tips for Difficult DVT Scans – Mrs Yvonne Butcher	Tertiary Scanning – Dr David Nyberg	The 18 Week Scan – Mrs Shirley Comminos
4.00 pm–5.00 pm	Ultrasound of the Appendix – Mr Richard Allan	Renal Artery Doppler Ultrasound, the Challenges – Mrs Yvonne Butcher	Ultrasound of the Postoperative Shoulder – Dr Carlo Martinoli	The 18 Week Scan – Mrs Shirley Comminos
ASUM 2007 Faculty Speakers and Major Sponsors dinner – by invitation only				

Friday, 14th September 2007

Plenary Session

9.00 am–10.00 am	Tissue Engineered Vascular and Urogenital Grafts – Dr Julie Campbell
10.00 am–10.30 am	Liver Abscesses; Imaging and Treatment Guided by Ultrasound – Prof Torben Lorentzen

10.30 am–11.00 am Morning Tea – Exhibition

Concurrent Sessions	Musculoskeletal	Vascular	Breast & Small Parts
11.00 am–11.30 am	Upper Limb Intervention – Dr Eugene McNally	Peripheral Vascular Disease – Lower Extremity Imaging Including Stents and Grafts – Ms Deb Coghlan	Sonographic Assessment of Extent and Aggressiveness of Malignant Breast Nodules – Dr Tom Stavros
11.30 am–12.00 pm	Brachial Plexus Ultrasound – Dr Carlo Martinoli	Doppler Ultrasound in the Functional Assessment of the Cerebral Circulation – Prof David Evans	Rural and Remote Breast Diagnosis – Dr Susane Fraser
12.00 pm–12.30 pm	Sports Medicine in Real Life – Dr Shane Brun	Duplex and the Surgeon: Great Expectations – Dr Roxanne Wu	Scrotum – Mr Stephen Bird

12.30 pm – 1.30 pm Lunch – Exhibition

1.30pm–2.00 pm Symposia by Sponsors

Concurrent Sessions	Small Parts	Musculoskeletal	Vascular
2.00 pm–2.20 pm	What Thyroid Nodules Need FNA According to the SRU Consensus Panel – Dr Tom Stavros	Lower Limb Interventional Procedures – Dr Eugene McNally	Carotid Intima – Media Thickness (cIMT) – Dr Joseph Polak
2.20 pm–2.40 pm	Salivary Glands – Mr Stephen Bird	Ultrasound of Ankle Tendons – Dr Carlo Martinoli	Upper Extremity Vascular Disorders/Imaging – Ms Deb Coghlan
2.40 pm–3.00 pm	Breast/Mammogram Correlation – Dr Tom Stavros	Ultrasound in Small Joint Arthritis – Dr Eugene McNally	Ultrasonic Detection of Cerebral Emboli – Prof David Evans

3.00 pm – 3.30 pm Afternoon Tea – Exhibition

Plenary Session

3.30 pm – 4.00 pm	Cerebral Embolism Research in Leicester – Prof David Evans		
Concurrent Sessions	Vascular	Musculoskeletal	Urology & Gynaecology Room
4.00 pm–4.20 pm	Salvaging the Diabetic Foot – A Short Talk About Short Bypasses – Dr Christina Steffen	Ultrasound of the Shoulder – Dr Eugene McNally	Pelvic Floor Ultrasound – The Basics – Assoc Prof Hans Peter Dietz
4.20 pm–4.40 pm	Recent Developments in Doppler Ultrasound – Prof David Evans	Ultrasound of Entrapment Neuropathies of the Upper Extremity – Dr Carlo Martinoli	Visualising Grafts in Gynaecological Surgery – Prof Ajay Rane
4.40 pm–5.00 pm	Abdominal Aortic Aneurysms (AAA) Screening – Dr Joseph Polak	Ultrasound of the Ankle – Dr Eugene McNally	Pelvic Floor Trauma – Assoc Prof Hans Peter Dietz
Proffered Papers	Vascular	Musculoskeletal/General	Obstetrics
5.00 pm–5.10 pm	The Day One Renal Transplant Doppler Assessment – Mr Alan Williams	Reference Values for Sonographic Measurements of the Ulnar Nerve at the Elbow – Ms Kerry Thoires	The Outcome of Pregnancies of Unknown Location According to the Mother's Age and Gestational Age – Assoc Prof George Condous
5.10 pm– 5.20 pm	High Frequency Ultrasound for the Measurement of Dedema in Chronic Venous Disease – Dr Antonina Volikova	Turning Astronauts into Sonographers: Assessing the Clinical Utility of Ultrasound on Board the International Space Station (ISS) – Ms Marilyn Zelesco	What Measurements Are Needed to Predict Pregnancy Outcome in Pregnancies of Unknown Location: Does Measuring hCG suffice? – Assoc Prof George Condous

5.20 pm–7.00 pm Welcome reception – Hall and C and D Exhibition

Scientific Meeting 2007

Saturday, 15th September 2007

Plenary Session

9.00 am–9.30 am	Novel First Trimester Markers for Down Syndrome – Dr Jon Hyett
9.30 am–10.00 am	Labour Ward Ultrasound – What, When & Why? – Prof David Ellwood
10.00 am–10.30 am	Increased Nuchal Translucency with Normal Karyotype – Prof Yves Ville

10.30 am–11.00 am Morning Tea – Exhibition and AGM

Concurrent Sessions	Obstetrics	Musculoskeletal	Vascular/Interventional Ultrasound
11.00 am–11.20 am	Management of Multiple Pregnancies – Dr Robert Cincotta	Sonography of the Sacrotubous Ligament – Dr Neil Simmons	Diagnostic Test Algorithms – Dr Joseph Polak
11.20 am–11.40 am	Outcomes of Pregnancies Referred with Preterm Prelabour Rupture of Membrane – Dr Jon Hyett	Ultrasound of the Wrist and Hand – Dr Carlo Martinoli	Ultrasound Guided RF-Ablation of Liver Tumors – Prof Torben Lorentzen
11.40 am–12.00 pm	Abnormalities of Amniotic Fluid – Dr David Nyberg	Sonography of Retinacular and other Fascial Structures – Dr Neil Simmons	Simplifying the Ultrasound of Post-Endovascular Intervention for Aneurysmal Disease – Mr Brendan Cramp
12.00 pm–12.30 pm	Prenatal Diagnosis of Genetic Syndromes – Dr Jon Hyett	Sports Medicine: Beyond Real Life – Dr Shane Brun	Carotid IMT (cIMT): Protocols and Approaches – Dr Joseph Polak

12.30 pm–1.30 pm Lunch – Exhibition

Concurrent Sessions	Musculoskeletal	Obstetrics	Gynaecology and Renal
1.30 pm–2.00 pm	Sonography of Lower Limb Nerve Entrapments – Dr Neil Simmons	The Gravid Cervix – Dr David Nyberg	Mistakes Made in OBGYN Imaging and Reporting – Dr Kerry McMahon
2.00 pm–2.30 pm	Shoulder Ultrasound Beyond the Rotator Cuff – Dr Carlo Martinoli	Fetal Infections – Prof Yves Ville	Ultrasound for the Pelvic Floor Surgeon – Assoc Prof Hans Peter Dietz
2.30 pm–3.00 pm	Sonography of Bursae – Dr Neil Simmons	The 2nd Trimester Sonogram – Dr David Nyberg	Ultrasound in Nephrology – Prof Torben Lorentzen

3.00 pm–3.30 pm Afternoon Tea – Exhibition

Concurrent Sessions	Obstetrics	Gynaecology & Early Pregnancy	Proffered Papers
3.30 pm–3.50 pm	Use of 3D Ultrasound – Dr David Nyberg	Early Pregnancy Failure – The Role of Assessment Units – Prof David Ellwood	Diagnosis of fetal CNS Using US and MRI – Dr Guowei Tao
			US Assessment of the Effects of Smoking in Pregnancy on Endothelial Function – Ms Ann Quinton
			Prenatal Sonographic Diagnosis of Aberrant Fetal Sulcation – Mr Peter Coombs
3.50 pm–4.20 pm	Fetal Therapy: What the Sonographer Needs to Know – Dr Rob Cincotta	Imaging the Uterus: From Congenital Anomalies to Post Menopause – Dr Kerry McMahon	Does Postnatal Cerebellar Growth Predict Developmental Outcome At 2 Years of Age in Very Preterm Infants? – Dr Sheryle Rogerson
			Fetal Anatomy Assessed by Three-dimensional Ultrasound at 11–13+6 Weeks Gestation, Correlated With the 18–20 Week Scan and Postnatal Outcomes – Mr David Fauchon

4.20 pm–5.30 pm Poster Defence Session – Hall C&D Exhibition

7.00 pm–12.00 midnight ASUM ASM Gala Dinner – Hall 2

Sunday, 16th September 2007

Concurrent Sessions	Obstetrics	Gynaecology	General
9.00 am–9.20 am	Fetal Syndromes – Dr David Nyberg	Ultrasound of Implants in Pelvic Reconstructive Surgery – Assoc Prof Hans Peter Dietz	Percutaneous Gastrostomy Guided by Ultrasound and Fluoroscopy – Prof Torben Lorentzen
9.20 am–9.40 am	Managing Monochorionic Twin Pregnancies – Dr Jon Hyett	How Useful is Ultrasound in the Management of Secondary PPH? – Prof David Ellwood	Ultrasound of Chronic Liver Disease – Dr Richard Allan
9.40 am–10.00 am	3D Ultrasound in the 1st Trimester – Dr Robert Cincotta	Prediction of Emergency Operative Delivery and Pelvic Floor Trauma – Assoc Prof Hans Peter Dietz	Peyronies Disease – the Long and the Short of It – Mrs Michelle Pedretti
10.00 am–10.30 am	Fetal Brain – Prof Yves Ville	Saline Hysterosonography – a Useful Adjunct to the Gynaecological Scan – Prof David Ellwood	Interventional Ultrasound: the Basics – Dr Matthew Andrews

10.30 am–11.00 am Morning Tea – Exhibition

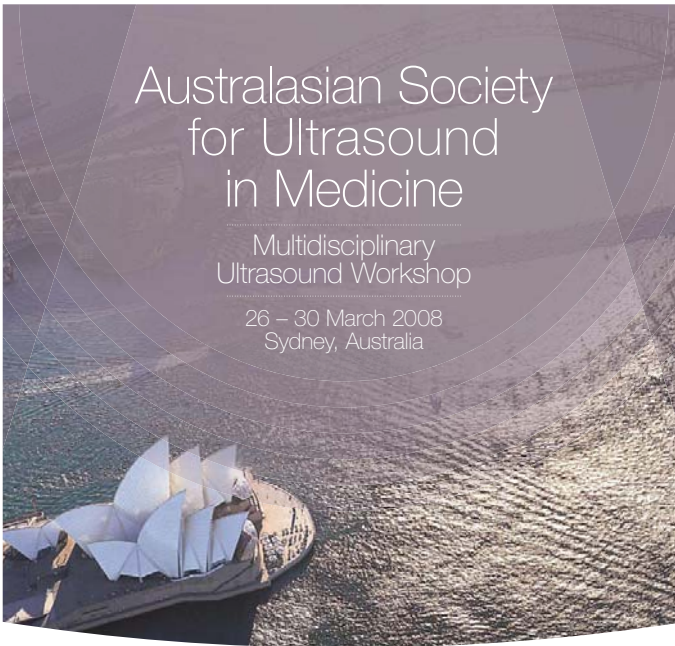
Plenary Session – Hall A

11.00 am–11.30 am	Liver Doppler – Dr Richard Allan
11.30 am–12.00	The Pivotal Role of Ultrasound in IVF – Before, During and After – Dr Robert Miller
12.00 noon–12.30 pm	An Update on Fetal Therapy – Prof Yves Villes

12.30 pm Finish



ASUM extends a warm welcome to you at upcoming ASUM meetings



Australasian Society for Ultrasound in Medicine

Multidisciplinary
Ultrasound Workshop

26 – 30 March 2008
Sydney, Australia

Convenors

Dr Glenn McNally
Dr Susan Campbell Westerway
Mrs Jenifer Kidd
Mrs Margaret Condon

Associated Meetings

DDU Technical Seminars
26–27 March 2008

DMU Preparation Courses
26–30 March 2008

PO Box 943 Crows Nest NSW 1585, Sydney, Australia
Tel: +61 2 9438 2078 Fax: +61 2 9438 3686
Email: asum@asum.com.au Website: www.asum.com.au



Australasian Society for Ultrasound in Medicine

37th Annual Scientific Meeting

13 – 16 September 2007
Cairns Convention Centre
Cairns, Australia

Promoting Excellence in Ultrasound

ASUM Head Office
PO Box 943
Crows Nest NSW 2008
Australia
Telephone: +61 2 9438 2078
Facsimile: +61 2 9438 3686
Email: asum@asum.com.au
Website: www.asum.com.au

Meeting Office
ICMS Pty Ltd
Locked Mail 04002
QVB Post Office
Sydney NSW 1230
Australia
Telephone: +61 2 9299 3366
Facsimile: +61 2 9299 4444
Email: asum2007@icms.com.au
Website: www.asum2007.com

ASUM is Certified ISO 9001:2000 Quality Management Systems
ASUM is affiliated with WFUMB

Critical Dates
 Proffered Paper & Poster Abstract Submission Deadline
Friday, 11 May 2007
 Proffered Paper & Poster Abstract Notification
Friday, 22 June 2007
 Early Bird Registration Deadline
Friday, 13 July 2007
 Accommodation Deadline
Monday, 6 August 2007

www.asum2007.com

WFUMB 2009 Sydney Australia

12th World Congress of the
World Federation
for Ultrasound in
Medicine and Biology
August 30 – September 3, 2009

WFUMB 2009 Congress Office
c/o ICMS Pty Ltd
Locked Bag 04002
QVB Post Office
Sydney NSW 1230
Australia
P: +61 2 9299 3366
F: +61 2 9292 2444
E: info@wfumb2009.com
W: www.wfumb2009.com

Sydney Convention and Exhibition Centre

WFUMB 2009 Aims to

- Accommodate** new developments and applications of ultrasound in medicine
- Share** a common global goal of establishing high standards for safe and effective use of ultrasound in medicine
- Provide** an ideal forum to join with peers and colleagues in ultrasound from all around the world
- Provide** a successful scientific, educational and social congress in this modern and beautiful city

www.wfumb2009.com

Australasian Society for Ultrasound in Medicine

Upcoming ASUM MEETINGS

ASUM 37th Annual Scientific Meeting 2007
Cairns, Australia, 13th–16th September 2007
Go to www.asum.com.au for more details

ASUM Multidisciplinary Workshop 2008
Sydney, Australia, 26th–30th March 2008
Go to www.asum.com.au for more details

WFUMB 2009
12th Congress of the World Federation for Ultrasound in Medicine and Biology
Sydney, Australia, 30th August–3rd September 2009
Go to www.asum.com.au for more details

ASUM contacts
Chief Executive Officer Dr Caroline Hong
Email: carolinehong@asum.com.au
Education Manager Mr Keith Henderson
Email: khenderson@asum.com.au

ASUM Head Office
PO Box 943 Crows Nest NSW 1585 Sydney, Australia
Tel: +61 2 9438 2078 Fax: +61 2 9438 3686
Email: asum@asum.com.au Website: www.asum.com.au

Promoting Excellence in Ultrasound

WWW.ASUM.COM.AU

Minister opens new ASUM office

Address by Dr Matthew Andrews, President of the Australasian Society for Ultrasound in Medicine, on 28th June 2007 at the official launch and opening of the new ASUM office by the honourable Tony Abbott MHR, Minister for Health and Ageing

Minister Abbott, representatives of various medical colleges and societies, Ultrasound Companies, Life Members, Honorary Fellows, Past Presidents, Staff and members of ASUM, supporters and friends of ASUM.

Today marks an important milestone in the history of medical ultrasound in Australasia.

We are privileged to have such a prestigious audience to officially open our new offices. Tonight, however, is much more than bricks and mortar. It reflects the crucial role ultrasound has come to play in modern medicine.

What an amazing thing it is to be able to see inside the human body! This ability has revolutionised the practice of medicine – and, in our unbiased view, what better way to do it than with ultrasound?

The whole basis of our Society is the simple fact that when high frequency sound waves are introduced into the body, images of internal structures can be obtained from the reflected sound waves.

From rudimentary beginnings about 30–40 years ago, when the images consisted of black and white lines, ultrasound has evolved into the incredibly sophisticated representations of the human body in the fourth dimension as you can see here tonight.

Australia has always been at the forefront of pioneering ultrasound technology, paralleled by the development of this Society which formed in 1970 with 13 foundation members. Our membership has grown to over 2500 comprising:

- Medical practitioners for various specialty disciplines;
- Sonographers – the highly skilled technologists who produce a large proportion of ultrasound images used today;
- Scientists; and
- Ultrasound industry representatives.

ASUM is unique in bringing together such a wide variety of medical practitioners in a cooperative, plus all



Dr Matthew Andrews

the team members who all contribute to an ultrasound service.

On a personal note, I would have to add that ASUM has always been a society which has broken down petty rivalries amongst different medical craft groups – we have radiologists, obstetricians, surgeons, sonographers all collaborating, which is truly amazing. The ultimate beneficiary is ultrasound, but there is also the fringe benefit of being a friendly and sociable organisation.

Ultrasound is now widely utilised in a variety of clinical settings for diagnosis, intervention and therapy and there are few fields in medicine where ultrasound does not play a role. Applications of medical ultrasound are found in the abdomen, obstetrics and gynaecology, many surgical subspecialties, paediatrics, cardiology, oncology, urology, breast and sports medicine to name but a few.

Ultrasound is an integral part of the array of imaging modalities used to look inside the body, allowing earlier and earlier diagnosis and management of illness. It has the advantages of no radiation, portability, real-time visualisation and being relatively inexpensive. In many instances ultrasound has replaced surgical procedures, eliminating the associated inherent risks and costs. New applications of ultrasound are developing as machines become more advanced, but paradoxically more user friendly, compact and affordable. Clinicians increasingly use ultrasound as a tool in their every day practice where it is becoming the 'sophisticated stethoscope' at the point of patient care.

Minister, you and your department are probably aware of ultrasound utilisation growth rates often outstripping other modalities including x-rays, CT scans and nuclear medicine, reflecting these new applications of ultrasound.





What is ASUM's role?

In view of its large and comprehensive membership covering every aspect of ultrasound service provision, ASUM is the definitive ultrasound authority in this country and it is simply dedicated to *Excellence in Ultrasound*.

How does it do this?

- Promotes and supports ultrasound research and disseminates ultrasound-related scientific information via a range of activities.
- Provides a wide range of educational services and qualifications. Until recently these have been dedicated solely to medical imaging specialists and sonographers, but now expanding to fulfill the specific needs of clinicians at the point of patient care. ASUM established the DDU (Diploma of Diagnostic Ultrasound), the first specific medical ultrasound qualification and the DMU (Diploma of Medical Ultrasonography) the original medical sonographer qualification and recently awarded the first CCPU (Certificate of Clinician Performed Ultrasound) for non-imaging specialists utilising ultrasound at the point of clinical care.
- Sets standards of ultrasound practice
- Addresses ultrasound safety issues, bearing in mind that ultrasound is probably, but not necessarily safe.
- Actively collaborates with government authorities to ensure they are advised of resourcing for ultrasound services, including appropriate utilisation. We are pleased to have cooperated with the Department of Health and Ageing on many specific issues.

What do these new premises signify?

This building provides the state of the art facilities required by ASUM to provide services to its members and through them, the highest quality ultrasound services to their patients. Everyone here tonight, including Mr Abbott has a role in the provision in ultrasound services, so please utilise ASUM and this new headquarters as your ultrasound resource.

This facility is also a fitting home for ASUM's other major future activities, the most ambitious being hosting the World Federation of Ultrasound in Medicine and Biology (WFUMB) World Congress in Sydney in just over two years time. We expect over 5000 registrants. ASUM's Asia-Link Program, promoting academic exchanges and collaboration between Australian and New Zealand and the Asian region will also be well housed in this building.

So in summary, today is a big day for ultrasound in Australia and New Zealand. This facility reflects the excellent service and dedication ASUM members and staff have to their profession and thus to their patients. We are proud to display it to our guests here tonight and trust that whenever you think of ultrasound, you will think of ASUM.

Finally, on behalf of ASUM Council, I would like to pay tribute to Dr Caroline Hong and the ASUM team, who have made this move a reality. Without Caroline's dedicated leadership, this and many of ASUM's other visionary activities would not occur. I now invite the Hon Tony Abbott, Federal Health Minister, to say a few words to and officially open ASUM's new headquarters.

Dr Matthew Andrews
President



Another historic moment for ASUM

Address by the Hon Tony Abbott, MHR, Minister for Health and Ageing, at the official opening of the new ASUM office in St Leonards NSW



The Hon Tony Abbott

Thank you ladies and gentlemen for making me feel welcome here in this sparkling new office. I am not a doctor; I am not an allied health professional – just a politician. That in some way makes me perhaps a less-sophisticated Minister. That might be the case but, in other ways perhaps, it makes it easier because I am not caught up in the

ordinary politics of health.

In particular, in the medical profession and having seen the politics of health up close over the last 3½ to 4 years, some of you guys can play politics more ferociously than we politicians and members of Parliament.

So, I am particularly delighted to come to a Society which manages to combine doctors in various specialties and allied health professionals, in such a tranquil and harmonious relationship. I think this is a model which should be more widely emulated in the health sector generally.

So I am pleased to say to all of you, well done!

Thanks for the contribution that you've made.

Yes, even politicians have kids and I suppose, like most parents these days, my first acquaintance with my kids was looking at them on an ultrasound screen. To watch the baby's heart beating, through the magic of ultrasound, is a pretty special moment and, obviously, most parents these days are incredibly grateful to one of your members or associates for bringing that to them, for the first time.

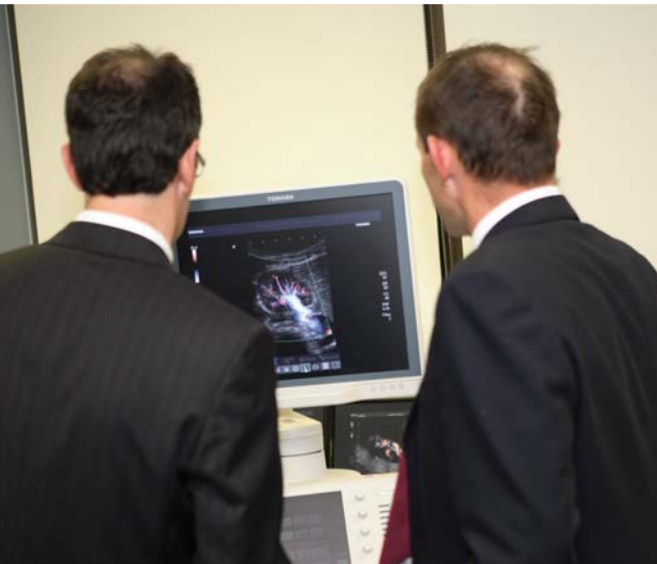
But ultrasound is useful and, indeed, vital in a wide range of diagnostic and analytical contexts these days, certainly, not just in an obstetric context. I am conscious of the fact that there are some 5 million Medicare rebates a year that pay for these ultrasound services.

I have no problem with that because, I'm sure, they are all necessary and cost-effective. I'm also conscious, as Dr Andrews said, of the very significant increase in the number of ultrasounds which are funded under Medicare and, again, I'm sure that is for the great benefit of patients.

So look, it is important that all of our health professionals are constantly improving their professional standards. I know that the Australasian Society for Ultrasound in Medicine is at the forefront of doing just that. So I have great pleasure in helping declare this marvellous new office officially open.

The Minister then went on to cut the ribbons to release the balloons to announce the ASUM office officially opened. Transcript.







MEDIA RELEASE**Federal Health Minister opens new facility for ultrasound specialists**

Federal Health Minister Tony Abbott opened the new headquarters of the Australasian Society for Ultrasound in Medicine (ASUM) at Level 2, 511 Pacific Highway, St Leonards at 5pm on Thursday 28th June 2007.

The move to new premises and the recognition from the Federal Health Minister is seen as a clear indication of the important role ultrasound now plays in everyday medical practice and the rapid development in medical ultrasound technology.

'The office opening and expansion of services to specialists in ultrasound also signifies the role that ASUM plays, not just in Australia but also in New Zealand, the close ties the two countries have in the development of ultrasound in medicine,' said ASUM President, Dr Matthew Andrews.

'Ultrasound is one of the most rapidly expanding branches of medicine and is used to examine most parts of the body including the detection of cancer and ever increasing detail in pregnancy,' he said.

ASUM's membership of more than 2600 includes medical specialists from multiple disciplines, sonographers, physicists, engineers, veterinarians, and the corporate sector.

ASUM has worked successfully over many years with technology companies such as Toshiba, GE Healthcare, Philips and Siemens in providing sonography education and maintaining high standards in diagnostic medical ultrasound.

'The primary role of ASUM is to disseminate scientific information, foster education, and to promote the highest standards of medical ultrasound practice in Australia and New Zealand,' Dr Andrews said.

Because of the strong focus on education and on-going training the new premises will feature two training rooms, a well equipped library, and state-of-the-art office facilities. ASUM will share the second floor facility with other medical and health related services.

'ASUM is a relatively young organisation, which started in 1970 with only 13 members. With the rapid growth in ultrasound as a diagnostic, interventional and now, also as a therapeutic tool, ASUM has developed into a peak body pertaining to education certification and standards of practice and, as such, is a major resource to the industry,' Dr Andrews said.

Advances in ultrasound technology include real-time 3D, detecting medical disorders in pregnancy, detection and intervention in breast cancer and female infertility.

In recognition of ASUM's world leadership status in providing services to ultrasound practitioners, the organisation has been awarded the right to host the world ultrasound congress, WFUMB 2009 in Sydney, which will attract more than 5000 international delegates to Australia.

For media interviews contact: Peter Russell on mob 0405 151 045 and for ASUM inquiries contact ASUM CEO Dr Caroline Hong on (02) 9438 2078.

AUSTRALASIAN SOCIETY FOR ULTRASOUND IN MEDICINE

ACN 001 679 161 ABN 64 001 679 161

PO BOX 943 CROWS NEST
NSW 1585 AUSTRALIA

tel +61 2 9438 2078 Fax +61 2 9438 3686

email asum@asum.com.auweb <http://www.asum.com.au>**NOTICE OF ANNUAL GENERAL MEETING 2007**

The 2007 Annual General Meeting of the Australasian Society for Ultrasound in Medicine will be held at the Cairns Convention Centre on Saturday 15th September 2007 at 10.30 am.

BUSINESS**1 MINUTES of the Annual General Meeting of 16th September 2006****2 ANNUAL REPORTS**

- 2.1 President
- 2.2 Honorary Secretary
- 2.3 Honorary Treasurer

3 FINANCIAL REPORT for the year ended 30th June 2007**4 ANNUAL SUBSCRIPTIONS for the year 2008–2009 as recommended by Council**

Medical / Scientific / Sonographer members	\$349.80
(\$335.50 if paid by 30th June 2008)	
Associate members	\$272.80
(\$261.80 if paid by 30th June 2008)	
Trainee members	\$272.80
(\$261.80 if paid by 30th June 2008)	
Retired members	\$118.80
(\$113.30 if paid by 30th June 2008)	
Corporate members	\$1303.50
(\$1251.80 if paid by 30th June 2008)	

(incl 10% GST for resident Australian members only)

Corresponding members – Ordinary	\$231.00
(\$222.20 if paid by 30th June 2008)	

Corresponding members – Associate	\$178.20
(\$171.60 if paid by 30th June 2008)	

5 ELECTION for 2007–2008 COUNCIL**6 LIFE MEMBER, HONORARY FELLOW, HONORARY MEMBER****7 GENERAL BUSINESS**

By order of the Council



Dr Caroline Hong
Chief Executive Officer

Every Medical / Scientific / Sonographer member of the Society is entitled to appoint a proxy, provided that the proxy form is deposited at the registered office of the Society (Level 2, 511 Pacific Highway, St Leonards NSW 2065, Australia) not less than twenty-four hours before the meeting.

A proxy form is included in the Annual Report mailed to all members who are eligible to vote at the meeting.

COUNCIL 2005–2007

EXECUTIVE

President

Matthew Andrews Vic
Medical Councillor

Immediate Past President

David Rogers NZ
Medical Councillor

Honorary Secretary

Roslyn Savage Qld
Sonographer Councillor

Honorary Treasurer

Andrew Ngu Vic
Medical Councillor

MEMBERS

Medical Councillors

Ron Benzie NSW
John Crozier NSW
Roger Davies SA
David Davies-Payne NZ

Sonographer Councillors

Stephen Bird SA
Margaret Condon Vic
Kaye Griffiths NSW
Michelle Pedretti WA

ASUM Head Office

Chief Executive Officer

Caroline Hong

Education Manager

Keith Henderson

All correspondence should be directed to:

The Chief Executive Officer
Australasian Society for
Ultrasound in Medicine
Level 2, 511 Pacific Highway
St. Leonards Australia
asum@asum.com.au
<http://www.asum.com.au>

CEO's message



Dr Caroline Hong

A lot has happened since my last message. The successful office opening by the Hon Tony Abbott, MHR, Minister for Health and Ageing on 28th June 2007, DMU and DDU examinations and the recent ASUM meetings and workshops were enough to keep ASUM volunteers and the ASUM Secretariat staff very busy.

Details of the historic official opening are published elsewhere in this issue.

AGM and Annual Report

The Annual Report and notice of the AGM, which will be held on Saturday 15th September 2007 at the Cairns Convention Centre, is included in the mailing to members who are eligible to vote.

Membership

I hope that many of you reading this issue have already renewed your membership subscription for the year 1st July 2007 to 30th June 2008. If you have overlooked this, it is not too late. If you have misplaced your renewal details, please contact ASUM at registrar@asum.com.au.

ASUM is proud to announce a steady increase in membership, as of 30th June 2007 there were 2644 members.

ASUM RANZCR NZ Branch joint meeting

This event was attended by close to 300 people from ASUM and the RANZCR memberships. Dr Hong Soo Wong was the ASUM Convenor, supported by

Christine Birchall. Terence Cousins, Rodney Wu and Lisa Sweetman were the RANZCR convenors, supported by Gail le Claire.

Joint meetings always bring bigger numbers and add life and zest due to the diversity and variety in the scientific and social programs. It also has its complexities in the organising of such an event.

It was a good outcome for all the delegates, exhibitors and for both ASUM and the RANZCR. On behalf of ASUM, we thank Hong Soo Wong and Christine Birchall for their hard work on the Organising Committee.

We also are grateful to the speakers including keynote speakers Prof Lil Valentin from Sweden, Assoc Prof Jon Hyett from Brisbane, Dr Debra Ikeda from California and Dr Phil Tirman from America and all the other supporting speakers, including Dr Billy Ying Kei Cheung, Martin Necas, Dr Ramesh Tripathi, Prof Kevin Pringle, Dr David Rogers, Ian Ross, Stephen Bird, Dr John Matthews and Dr Roger Davies.

Prof Fung Yee Chan, who was scheduled to be a keynote speaker, tragically passed away and we are grateful to Jon Hyett who took over most of her presentations.

We are also grateful for the support of the sponsors and exhibitors at this meeting, in particular Platinum Sponsor, GE Healthcare, Silver Sponsors Siemens, Philips and Carestream Health and Bronze Sponsor Comrad Medical Systems.

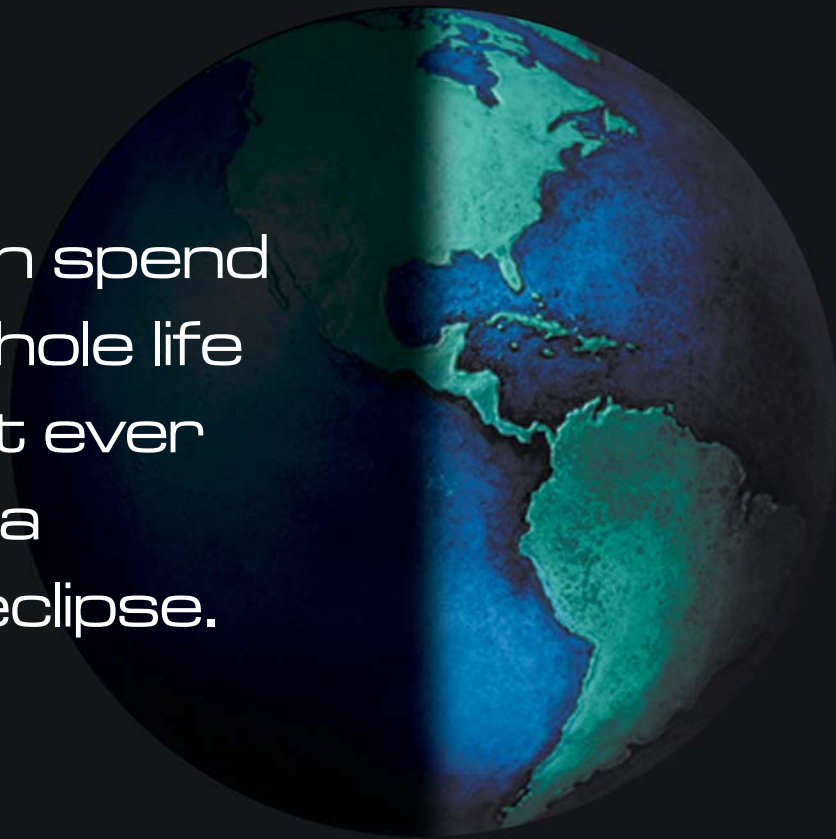WA Branch Meeting

Michelle Pedretti convened the WA Branch meeting at the Royal Perth Hospital on 30th June–1st July 2007. About 120 people attended this meeting, which proved once again the value of ASUM meetings in providing continuing education to members. The keynote speakers were Dr Cheryl Bass and Christopher Sykes,

WFUMB 2009
Sydney
Australia
12th Congress of the
World Federation
for Ultrasound in
Medicine and Biology
August 30 – September 3, 2009



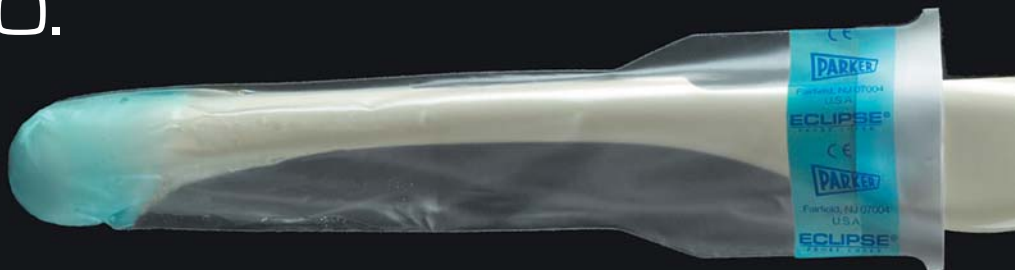You can spend
your whole life
without ever
seeing a
single eclipse.



Fortunately, our ECLIPSE[®]
is conveniently packaged
in boxes of 100.

From first contact you'll agree,
Eclipse Probe Covers provide
unmatched quality and economy.

- Soft, pliable, latex-free polyethylene film for endocavity ultrasound
- Conveniently pre-gelled with Aquasonic[®] 100 Ultrasound Transmission Gel
- Cost-effective, economically priced, and packed 100 per box
- Disposable, for single use
- One size fits most endocavity ultrasound probes



ECLIPSE[®]
PROBE COVER



Parker Laboratories, Inc.
286 Eldridge Road
Fairfield, NJ 07004
Tel: 973-276-9500 • Fax: 973-276-9510
www.parkerlabs.com

ISO 13485:2003

Only Eclipse Probe Covers are
conveniently pre-gelled inside
with Aquasonic[®] 100 Ultrasound
Transmission Gel, the world
standard for medical ultrasound.



supported by local 10 speakers, including Elizabeth Jane Wylie, Dennis Nelson, Bev Hewitt, Richard Langston, Narelle Hadlow, Jan Dickinson, Marilyn Zelesco, Rob Hart, Samantha Ward and Kirsty Milward.

This meeting also proved successful due to the support from Siemens, GE Healthcare, Toshiba and Philips.

Nancy Leong from the ASUM Secretariat provided most of the support administrative services for this meeting and did an excellent job, working with the convenor and the education manager.

Early Pregnancy and Gynaecological Scanning Foundation Theoretical Courses

This is the joint venture ASUM has undertaken with an university foundation; the aim was to help raise funds for a research fellow at the Nepean Hospital.

The courses were held in Melbourne and Sydney attracting close to 70 attendees. The successful program was convened by George Condous and supported by Monica Pahuja in Melbourne.

The main presenters were George Condous and Sashi Siva. Tom Bourne, unfortunately, had to cancel due to

illness but the courses still went ahead with positive feedback from the attendees.

Nancy Leong and Keith Henderson provided support from the ASUM office and we are grateful to George Condous for his hard work in many of the organisational aspects, including arranging sponsorships from GE Healthcare and Philips.

ASUM 2007 Cairns ASM

Registrations are coming in fast and we anticipate a large attendance at this attractive destination.

The array of international and local speakers promises an exciting scientific program, starting with a skills development workshop day on Thursday 13th September. The main annual scientific meeting will run from Friday 14th September to Sunday 16th September.

Accommodation is filling up fast as September is also a popular tourist season so it is advisable to book early to avoid disappointment.

Cairns has a tropical climate and is close to many attractions such as the Great Barrier Reef and Green Island, the Tjapukai Aboriginal Cultural Park, Atherton tableland, World Heritage Rainforests of the Daintree National Park and Cape Tribulation National

Park and the Kuranda Skyrail Gondola Cableway which extends for 7.5 km over the rainforest.

A lot of information can be found on the website about Cairns at www.cairns.qld.gov.au/tourism/about_cairns.html.

To register for the ASUM 2007 Cairns meeting, please go to www.asum2007.com.

ASUM member receives USA award

ASUM members will be interested to learn that Kathryn Busch has been selected by the Society for Vascular Ultrasound in the USA as the recipient of the 2007 Excellence in Oral Clinical Presentation Award, for her clinical presentation at the 2007 SVU Annual Conference in Baltimore. Her topic was *Ultrasound detection of intermittent and position dependent endoleaks: evidence for a novel mechanism*.

This is the second year that she has won a prestigious award at the major US vascular technologists meeting, a great achievement for an Australian sonographer. Congratulations Kathryn.

Dr Caroline Hong
Chief Executive Officer
carolinehong@asum.com.au

Distributed in Australia by

<p>• AQUASONIC® 100 ULTRASOUND TRANSMISSION GEL * US 01-50 5 litre SONICPAC® with dispenser, 1 per box, 4 per case *US 01-08 0.25 litre dispenser, 12 per box</p>	<p>• SCAN® ULTRASOUND GEL * US 11-285 SCANPAC® contains: 4 SCAN gallons, 2 dispenser bottles 1 dispenser pump</p>
<p>• STERILE AQUASONIC® 100 ULTRASOUND TRANSMISSION GEL * US 01-01 20g over wrapped sterilized foil pouches 48 per box</p>	<p>• AQUAGEL® LUBRICATION GEL * US 57-15 150gram tube, 12 per box</p>
<p>• AQUASONIC® CLEAR® ULTRASOUND GEL * US 03-50 5 litre SONICPAC® with dispenser, 1 per box, 4 per case</p>	<p>• ECLIPSE® PROBE COVER * US 38-01 2.57"/1.75" W x 9.5" L (64mm/44mm x 241mm) 100 per box, 6 boxes per case</p>
<p>• AQUAFLEX® ULTRASOUND GEL PAD - STANDOFF * US 04-02 2cm x 9cm gel pad, 6 pads per box</p>	<p>• THERMASONIC® GEL WARMER * US 82-04-20CE Multi-bottle gel warmer</p>
<p>• POLYSONIC® ULTRASOUND LOTION * US 21-28 1 U.S. gallon with dispenser bottle, 4 per pack</p>	<p>• TRANSEPTIC® CLEANSING SOLUTION * US 09-25 250ml clear spray bottle, 12 per box</p>

516 Creek Street, Albury, 2640 Australia

Telephone: 02 6021 8222 Email: info@jacobsmedical.com.au
 Facsimile: 02 0621 7270 Website: www.jacobsmedical.com.au
 Free Call: 1800 021 928

Practical Ultrasound Training With the AIU

SPRING IS IN THE AIR

Spring clean your ultrasound skills with one of our many programs.

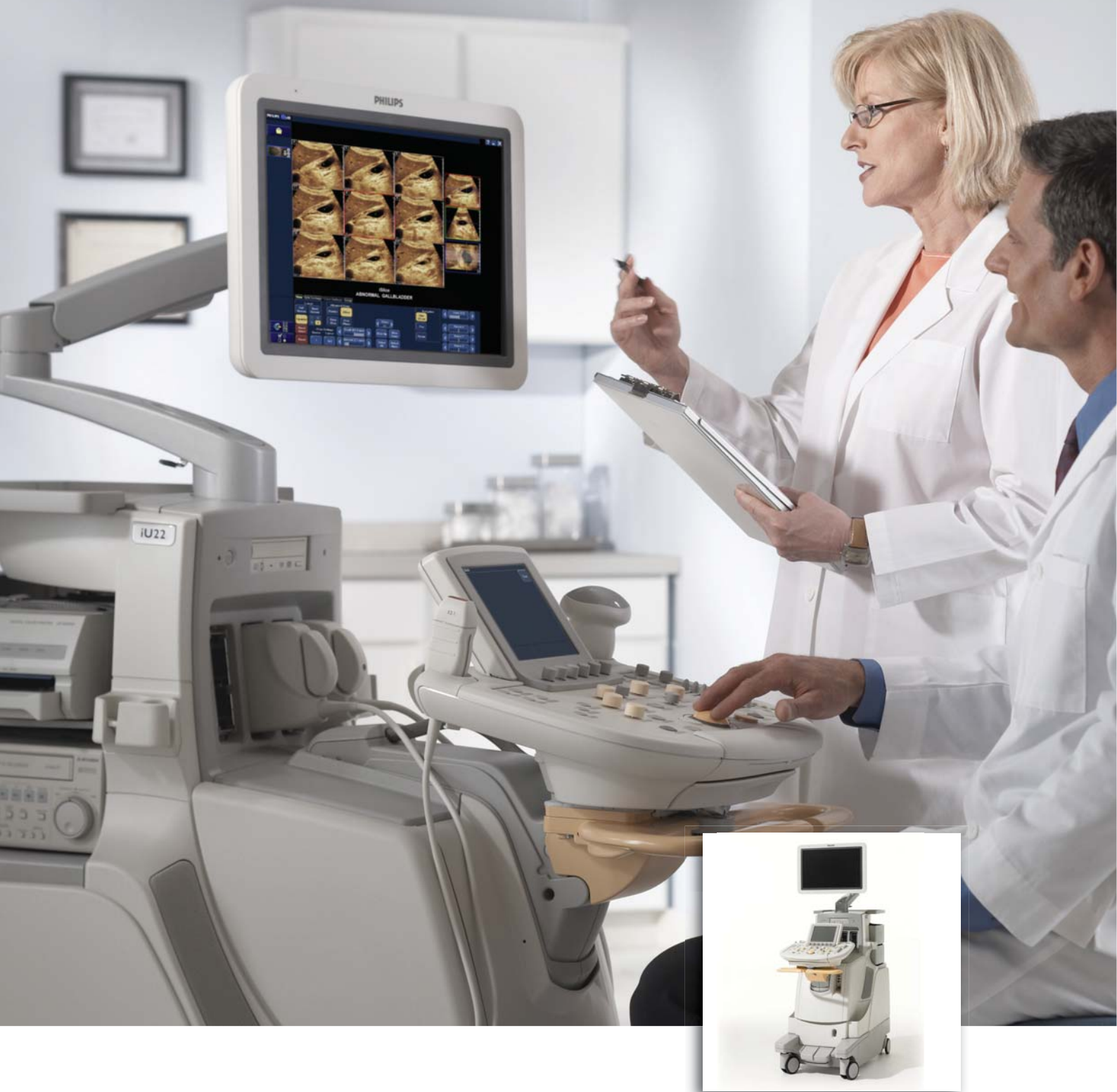Sample of upcoming programs:

- Sept 10th–12th – Ultrasound Techniques for Breast Surgeons
- Sept 24th–28th – O&G FastTrack Workshop
- October 1st–12th – New Entrant Sonographer FastTrack
- October 18th–19th – Ultrasound in Renal Dialysis
- October 29th–31st – Train The Trainer in Sonography

Come and join us, have fun & learn new skills. Check the website or your annual booklet for dates, or just give us a call.

Find out more, contact us:
 on-line www.aiu.edu.au
 Email: info@aiu.edu.au
 Phone: (07) 5526 6655
 Fax: (07) 5526 6041





Expand your vision and visualise in dimensions.

Today's Philips ultrasound advances make it possible to get more with less. This is especially true for volumetric imaging. When you integrate advanced volume imaging into your exams, you can decrease the acquisition time of the exam because you are acquiring a few volume sets instead of 30 or 40 images to complete the study. More information, in less time. It just makes sense.

To learn more, simply contact Philips 1800 251 400 (Aust) 0800 251 400 (NZ) or email pmsa.contactus@philips.com

www.medical.philips.com/au

PHILIPS
sense and simplicity

Pour encourager les autres!



Prof Ron Benzie

Sometimes authors wonder whether anyone pays much attention to their published efforts. Well, the following anecdote might help dispel concern. This week one of our young sonographers proudly showed me images she had taken in the Radiology Department on a patient with biceps brachii tendonosis. She had read Stephen Bird's article in the Bulletin (SJ Bird

ASUM *Ultrasound Bulletin* 2007; 10 (2): 24–29) detailing a new method for ultrasound evaluation of the distal biceps brachii tendon. She used this knowledge to get excellent views of the biceps brachii insertion and made the correct diagnosis; a fine example of an educational article influencing practice. And another incentive for budding authors to emulate Bird whose energy and enthusiasm is again illustrated in his article on iliopsoas tendon visualisation in this issue.

We also have an opinion piece by Mongelli who has an impressive number of publications on fetal growth and its evaluation.

The importance of patient position when examining the lower limb veins for reflux using Doppler is emphasised by Cairnduff.

Hassall has provided a review of the emergence of sonography as a profession. This is required reading for all sonographers, bearing in mind that this is a personal viewpoint by a long-term participant in the profession.

Micallef presents a case review of a fatal skeletal dysplasia. So we have something for everyone – musculoskeletal, fetal, obstetric, vascular and historical.

A new feature 'Scanning the Journals' by Gleaner (who modestly wishes to remain anonymous) will, in each issue, give a précis of journal articles which may be of interest. Items for inclusion in this endeavour are welcomed.

Continuing with our plans to strengthen the international standing and the content of the *Ultrasound Bulletin*, we're delighted to welcome four members to our newly constituted International Medical Board: Dr Bernard Benoit, the renowned French sonologist, who paid a visit to Australia recently; Dr Pavulos Sladkevicius of the University of Malmö, Sweden; Dr Gurleen Sharland of Guy's and St Thomas' Hospital, London; and Prof Alan Cameron of the Queen Mother's Maternity Hospital, Glasgow.

And finally, an abject apology to Dr A Joseph who mysteriously morphed from Anthony to Andrew in the May issue. He has written an interesting piece (on page 50 of this issue) that asks and answers the question 'Why do we need the CCPU?'

Ron Benzie
Editor

Email benzie@wahs.nsw.gov.au

Front cover image: 3D of IUD and viable pregnancy.

Narelle Kennedy AMS, Senior Sonographer
Christopher Kohlenberg Department of Perinatal Ultrasound, Nepean Hospital.

A 22-year-old, gravida 3, attended the Perinatal Ultrasound Department at Nepean Hospital after she discovered she was pregnant. The patient had previously had an IUD inserted as her primary method of contraception.

A dating ultrasound was requested and on examination a viable 18-week fetus was discovered. A full anatomy ultrasound was performed and was normal with a posterior placenta. The IUD was *in-situ*, found to be subchorionic and on the anterior wall. This was documented in 2D ultrasound.

A 3D ultrasound volume was obtained and the subsequent image is displayed on the front cover. The IUD is demonstrated at the level of the fetal neck appearing to be part of the fetus. This image demonstrates how overlying tissue in the volume, may be displayed on the 2D screen as part of the underlying fetus. A subsequent 3D image was obtained when the fetus had moved clearly demonstrates the device away from the fetus.

Pregnancy with an IUD is rare (<1%). If pregnancy occurs there is an increased risk of ectopic pregnancy. There is also an increased risk of miscarriage and this continues through to the second trimester. The risk of infection is high if the pregnancy continues and this may lead to preterm labour. The removal of the IUD is recommended, if possible, as soon as pregnancy is confirmed.

Reference

Sachs BP, Gregory K, McArdle C, Pinshaw A. Removal of retained intrauterine contraceptive devices in pregnancy. *Am J Perinatology* 1992 May 9 (3): 139–41.

To the Editor

As a non-ultrasound user, I was delighted to read a colleague's copy of the May 2007 issue of *Ultrasound Bulletin*. I edited *The Radiographer* for several years a couple of decades ago and appreciate the difficulties encountered in producing good clinical articles. Please accept my congratulations on the high quality of your publication.

Alex Barry

ORIGIN Industries
Australia's Premier remarketer of Diagnostic Imaging Equipment



To sell or buy equipment,
spare parts and xray tubes
please call (02) 9817 0955
or email
info@originindustries.com



www.originindustries.com



Detecting fetal growth restriction: can we improve on ultrasound techniques?

Max Mongelli

*Division of Women and Childrens' Health, Nepean Hospital, Penrith, New South Wales 2750, Australia.
Correspondence to Max Mongelli. Email max_mongelli@yahoo.com*

Outcome of current clinical practice

Effective monitoring of fetal growth remains an important aspect of obstetric care. By detecting intra-uterine growth restriction (IUGR) in its early stages, clinicians endeavor to minimise short-term complications such as stillbirth, prematurity, perinatal morbidity, and decreased fetal reserve during labour. Excessive fetal growth, on the other hand, is also deleterious as macrosomia is associated with birth trauma and neonatal metabolic disturbances.

In current practice, the clinical performance of screening methods for either macrosomia or IUGR remains poor. Screening policies for detecting the small for gestational age (SGA) baby using clinical methods succeed in only about a quarter of cases¹. An equally important question is whether antenatal detection improves outcome. A recent observational study in Germany, where frequent antenatal ultrasound scans are commonplace, suggested that those infants that were detected to be growth restricted in fact fared worse than those who were undetected, with a five-fold increase in preterm delivery rates and a three-fold increase in admission rates to neonatal intensive care². Furthermore, only 32% of IUGR infants were detected before delivery using ultrasound; the 80–90% detection rates reported in the literature can only be attained under research laboratory conditions and do not apply to most clinical settings.

Ultrasound criteria for the diagnosis of IUGR

There are no universally accepted criteria for the sonographic diagnosis of IUGR. This arises from the lack of generally accepted definitions for either intrauterine growth restriction or excessive fetal growth. For IUGR, Manning proposed a qualitative definition: '... a flattened growth velocity in which interval testing reveals a widening variance from expected growth velocity'³. The practical application of this definition is thus vulnerable to subjective bias. Another commonly used definition is 'failure to reach genetic growth potential'⁴. Apart from the lack of a quantitative element in defining genetic growth potential, this definition overlooks the fact that fetal growth is largely under maternal control rather than being driven by the fetal genome⁵.

Many textbooks make a distinction between symmetric and asymmetric IUGR using ultrasound criteria. Studies addressing this issue have failed to demonstrate any differences in clinical outcome on the basis of asymmetry⁶, and thus such criteria should no longer be used in routine practice.

Given that the diagnosis of IUGR is often unreliable, additional tests of fetal well-being should be applied to minimise the risk of preterm delivery through unnecessary intervention. Biophysical assessment of the fetoplacental unit, including Doppler studies of the uteroplacental circulation, have been shown to be useful in the management of such pregnancies⁷.

Reference standards

A variety of ultrasound reference standards have been published, and they may differ significantly from each other. Some of these differences may arise from ethnic variation e.g. femur lengths in Chinese fetuses have been found to be significantly shorter than in Caucasian fetuses⁸. In other cases, differences may be related to the statistical methodology in deriving the standard, or to the method of gestational age estimation. Standards in clinical practice are not always relevant to the ethnic composition of the local population being screened. For some ethnic groups, no adequate standards exist.

Maternal and pregnancy characteristics such as height, weight, parity and ethnic group have long been known to be strongly associated with birth weight, and these relationships have also been documented in several mammalian species⁹. These are physiological effects on fetal growth, but cannot be quantified in assessing growth in clinical practice.

Recently, computer software has been developed to generate individualised fetal growth charts that take these factors into account¹⁰. The GROW software (West Midlands Perinatal Institute, UK) plots customised growth curves for estimated fetal weight, but not the individual growth parameters. Retrospective studies suggest that fetal weight is a more efficient clinical parameter for growth screening than the fetal abdominal circumference alone¹¹. The charts have a dual y-axis, allowing plotting of both symphysis-fundus height and the estimated fetal weight. The estimated date of delivery is clearly displayed, and other data such as the maternal body mass index (BMI).

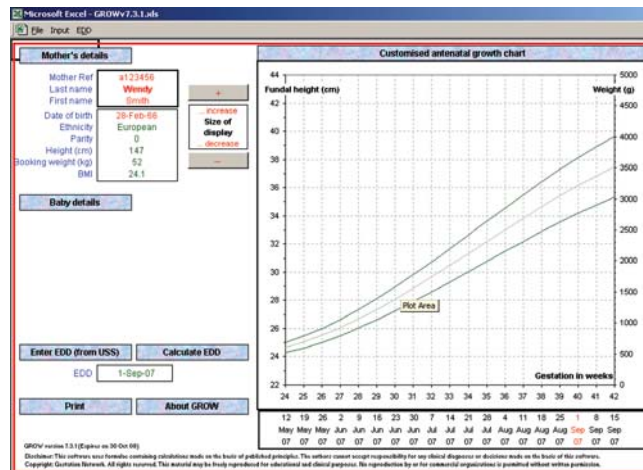


Fig. 1 Screen image of GROW software.

A screenshot of the software is shown in Fig. 1. The software for these charts, and other utilities, may be downloaded free of charge from the West Midlands Perinatal Institute at www.gestation.net.

Prospective studies have indicated that, compared with unadjusted standards, customised growth charts lead to improved clinical performance and reduced false positive rates in the detection of IUGR¹². A 'customised' definition of SGA birth weight was better correlated with adverse perinatal events than the local, unadjusted birth weight standard¹³.

Serial measurements and diagnosis of IUGR

There is great variation in clinical practice in how often ultrasound biometry scans are performed in screening for growth disturbances. Given that there is a significant error in ultrasound measurements, an apparent lack of growth from two ultrasound examinations may arise from an overestimate in the first measurement followed by an underestimate in the second measurement. We performed computer modeling studies to examine the relationship between frequency of ultrasound examination and the risk of false positive diagnoses for IUGR¹⁴. A steep rise in the false positive rates was noted as the frequency of scanning was increased. If the fetal abdominal circumference is used, the false positive rate at two-week intervals exceeds 16%. Similar findings confirming the validity of the computer model have been reported in recent field studies¹⁵.

A relatively new approach to identifying IUGR has been explored by Mondry *et al*¹⁶. The proposed method is based on the assumption that normally growing fetuses will track their growth percentiles. A downward crossing of percentile lines on serial ultrasound can be quantified non-parametrically by calculating the change in z-scores per unit of time (z-velocity), or dz/dt . A normal growth pattern will have dz/dt values close to 0, whereas an IUGR baby will have negative values. This method is awaiting independent evaluation.

Accuracy of fetal weight estimation by ultrasound

In many units, fetal growth screening is performed by calculating the estimated fetal weight (EFW) rather than the individual growth parameters. Some studies suggest this to be a better screening variable for IUGR¹⁴. However, there is great variation in performance with error rates of 90–350 g/kg commonly reported. Many of the ultrasound weight estimation formulae were derived from term fetuses, and may not work well at the extremes of gestational age. Additional confounding factors include inter-observer variability and differing demographic characteristics. In order to assess the potential confounding effects of ultrasound fetal weight formulae on growth screening, we completed a computer modelling study using British birth weight and ultrasound data. The model shows the potential for systematic overestimation or underestimation of differing weight formulae. We found that, in general, weight formulae tend to overestimate true weight at term and underestimate it in the preterm term. This effect was more pronounced with exponential formulae such as Hadlocks' than with volumetric formulae.

Can the performance of ultrasound be improved?

The potential of ultrasound examinations in screening for IUGR is probably not fully exploited. A common error is to equate SGA dates with growth restriction, and to deliver prematurely. A key aspect of the management of such cases is to perform a biophysical profile to assess fetal welfare; a normal biophysical profile would exclude serious cases of IUGR. Ultrasound examinations for growth should not be performed more often than once every three weeks, and ideally the measurements should be plotted as estimated fetal weight on customised growth charts.

References

- Hepburn M, Rosenberg K. An audit of the detection and management of small-for-gestational age babies. *Br J Obstet Gynaecol* 1986; 93 (3): 212–16.



- 2 Jahn A, Razum O, Berle P. Routine screening for intrauterine growth retardation in Germany: low sensitivity and questionable benefit for diagnosed cases. *Acta Obstet Gynecol Scand* 1998; 77 (6): 643–48.
- 3 Manning FA. Intrauterine growth retardation. In: Fleischer AC, Manning FA, Jeanty P, Romero R, eds. *Sonography in obstetrics and gynecology* 5th ed. Stamford Connecticut: Appleson and Lange; 1996.
- 4 Robinson JS. Fetal Growth. In: Turnbull A (ed). *Obstetrics*. London: Churchill Livingstone 1989; 141–42.
- 5 Brooks AA, Johnson MR, Steer PJ, Pawson ME, Abdalla HI. Birth weight: nature or nurture? *Early Hum Dev* 1995; 42 (1): 29–35.
- 6 Todros T, Piazzotta C, Pastorin L. Body proportionality of the small-for-date fetus: is it related to aetiological factors? *Early Hum Dev* 1996; 45 (1–2): 1–9.
- 7 Bobrow CS, Soothill PW. Fetal growth velocity: a cautionary tale. *Lancet* 1999; 353 (9170): 1460.
- 8 Shipp TD, Bromley B, Mascola M, Benacerraf B. Variation in fetal femur length with respect to maternal race. *J Ultrasound Med* 2001; 20 (2): 141–4.
- 9 Walton A, Hammond S. Maternal effects on growth and conformation in Shire horse-Shetland pony crosses. *Proceedings of the Royal Society* (1938), 125B: 311.
- 10 Gardosi J. Customized growth curves. *Clin Obstet Gynecol* 1997; 40 (4): 715–22.
- 11 Chang TC, Robson SC, Spencer JAD, Gallivan S. Identification of fetal growth retardation: comparison of Doppler waveform indices and serial ultrasound measurements of abdominal circumference and fetal weight. *Obstet Gynecol* 1993; 82 (2): 230–36.
- 12 Mongelli M, Gardosi J. Customising the fetal growth standard reduces the false positive diagnosis of intrauterine growth retardation. *Obstet Gynecol* 1996; 88 (5): 844–48.
- 13 de Jong CLD, Gardosi J, Dekker GA, Colenbrander GJ, vanGeijn HP. Application of a customised birth weight standard in the assessment of perinatal outcome in a high risk population *Br J Obstet Gynecol* 1998; 105 (5): 531–35.
- 14 Mongelli M, Ek S, Tambyrajia R. Screening for fetal growth restriction: A mathematical model of the effect of time interval and ultrasound error. *Obstet Gynecol* 1998; 92 (6): 908–12.
- 15 Owen P, Maharaj S, Khan KS, Howie PW. Interval between fetal measurements in predicting growth restriction. *Obstet Gynecol* 2001; 97 (4): 499–504.
- 16 Mondry A, Pengbo L, Loh M, Mongelli M. Z-velocity in screening for intrauterine growth restriction. *Ultrasound in Obstet Gynaecol* 2005; 26 (6): 634–8.

A new method for ultrasound evaluation of the iliopsoas tendon insertion

Stephen J. Bird

Benson Radiology, North Adelaide, South Australia 5006, Australia
Correspondence to Steven J. Bird. Email sjbird@ozemail.com.au

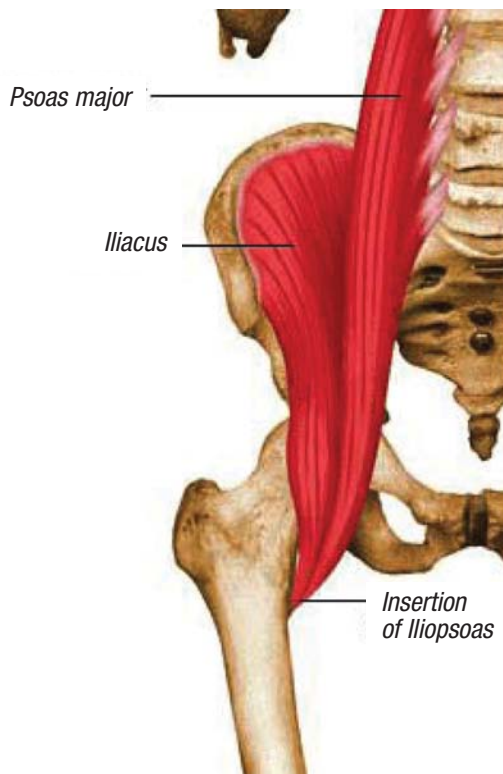


Fig. 1: Iliopsoas tendon formation from the musculotendinous fusion of the iliacus and psoas major muscles.

Iliopsoas is one of the most difficult tendon insertions to visualise sonographically.

The iliopsoas tendon is formed by the merging of muscle fibres arising from the iliacus and psoas major muscles to form a single tendon that inserts onto the lesser trochanter of the hip (Figs. 1, 2). The muscular component is well seen as it passes anterior to the iliopectineal eminence and the hip joint, however, the musculotendinous junction and tendon insertion onto the lesser trochanter are difficult to visualise sonographically with diagnostic clarity. Deep to the tendon lies the iliopsoas bursa which directly communicates with the hip joint in some, but not all, individuals. The iliopsoas bursa may be distended in the presence of virtually any pathological process which raises intra-articular hip pressure. If the bursa does not communicate with the hip joint it may still develop bursitis due to a variety of processes, including rheumatoid arthritis¹.

Sonography has a well-established role in evaluating the iliopsoas musculotendinous junction and the iliopsoas bursa. The dynamic nature of sonography is ideally suited for diagnosis of anterior snapping hip syndrome where the iliopsoas tendon snaps over the iliopectineal eminence². Snapping hip syndrome usually occurs in the absence of abnormal fluid

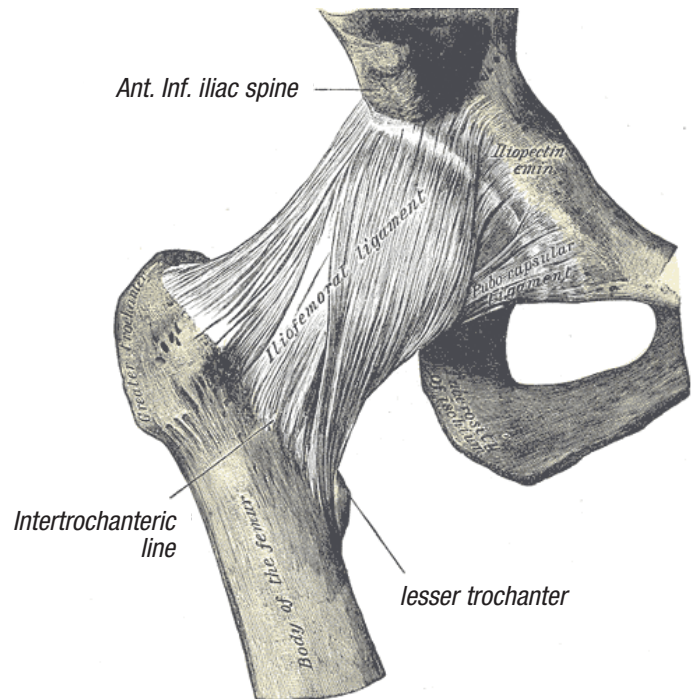


Fig. 2: Iliopsoas tendon insertion site on the lesser trochanter.

in the iliopsoas bursa². Iliopsoas tendonosis may occur as a solitary entity and appears as diffuse swelling of the iliopsoas tendon².

The use of sonography in these conditions has been based on transverse and longitudinal imaging of the iliopsoas musculotendinous junction at the level of the hip joint. Direct sonographic visualisation of the tendon insertion onto the lesser trochanter is often difficult or impossible.

Conventional sonographic technique

The sonographic technique for direct visualisation of the iliopsoas tendon insertion is to rotate the hip externally and scan from an anterior approach in the sagittal plane.

The image quality when using this conventional approach is hampered by a variety of physical limitations.

- 1) Anisotropy is impossible to overcome due to the deep diving course of the tendon toward the lesser trochanter. Real time compound imaging or beam steering technology combined with 'heel and toe' pressure cannot produce insonation perpendicular to the direction of the inserting tendon fibres in most cases.
- 2) The tendon insertion is located on the medial aspect of the lesser trochanter making direct sagittal visualisation difficult. External rotation of the hip will improve, but not completely overcome the problem (Fig. 2).
- 3) The tendon insertion is in a deep location, often many



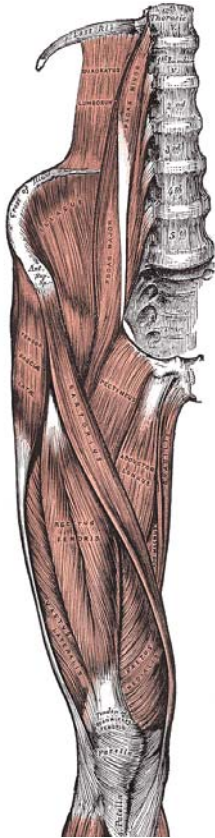


Fig. 3: Sartorius and pectineus muscle edges overlying the iliopsoas insertion combined with the femoral neurovascular bundle compromise the acoustic window for direct sagittal imaging.

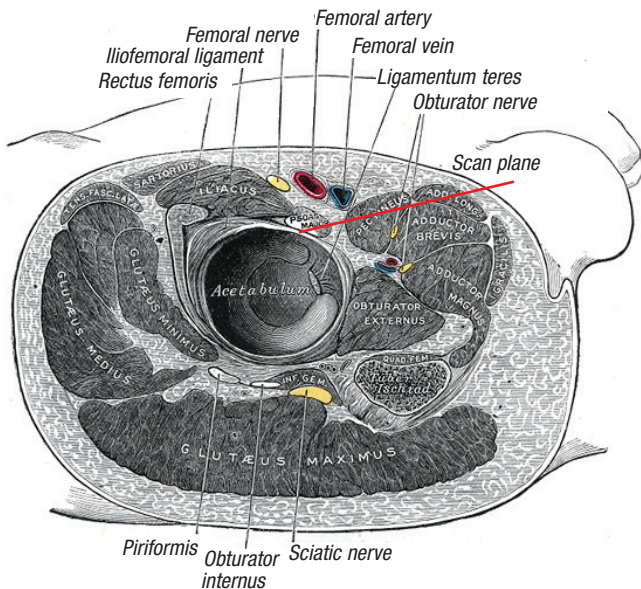


Fig. 4: The red line demonstrates a scan plane through adductor longus and pectineus muscle bellies providing an ideal acoustic window and avoids the femoral neurovascular bundle.

centimetres from the skin surface, requiring a lower frequency transducer of poorer spatial resolution capability to achieve adequate penetration.

- 4) When scanning from an anterior approach, the overlying sartorius, rectus femoris, vastus medialis and pectineus muscle belly edges lie immediately anterior to the iliopsoas tendon and result in refraction of the sound beam which degrades image quality significantly. This is akin to scanning an ovary or prostate through the midline of

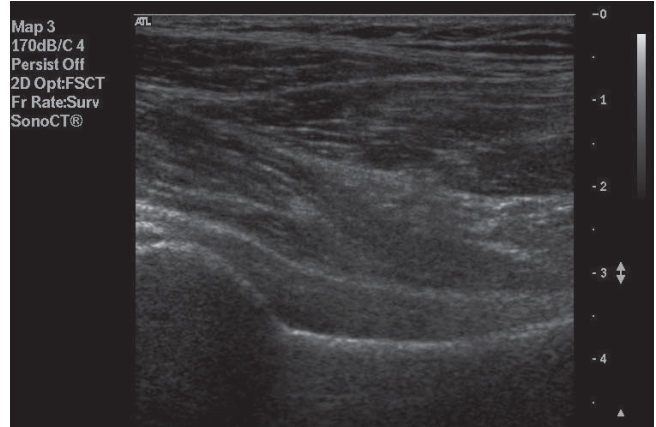


Fig. 5: Image of the hip in the standard mid sagittal plane.

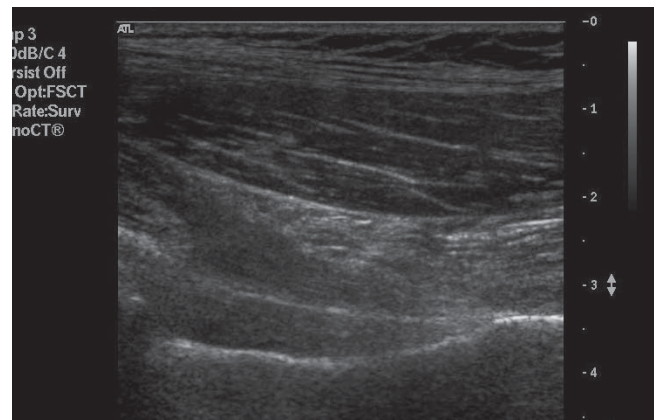


Fig. 6: Image just below the level of the capsule insertion on the intertrochanteric line.

the abdominal wall with refraction artifact generated by the rectus abdominus musculature. The location of the femoral neurovascular bundle also compromises the sagittal anterior acoustic window (Fig. 3).

The combination of a difficult to access tendon insertion in a deep location, angled steeply away from the transducer and overlaid with refraction-causing anatomical structures and fat, provides an imaging challenge that requires a new solution.

Alternative approach

The key to direct visualisation of the iliopsoas insertion onto the lesser trochanter is to use an alternative acoustic window. The tissues directly anterior to the insertion have very poor acoustic window properties and require high gain settings to provide adequate penetration. Scanning from a more medial position through the adductor longus and pectineus muscle bellies with an approach angled laterally towards the lesser trochanter has many advantages. The tissue path is through the centre of the muscle bellies rather than the edges, providing tendon insonation free of refraction artifact. This acoustic window avoids the many interfaces and fat contained within the femoral neurovascular bundle, which degrade image quality. The medial-to-lateral angulation of the scan plane allows direct access to the iliopsoas tendon insertion on the lesser trochanter, requiring only minor external rotation of the hip. With moderate heel and toe transducer pressure, the tendon is easily imaged perpendicular to the direction of the fibres, providing high-resolution images free of anisotropy artifact. Fig. 4 demonstrates the scan plane used to achieve the described acoustic window.

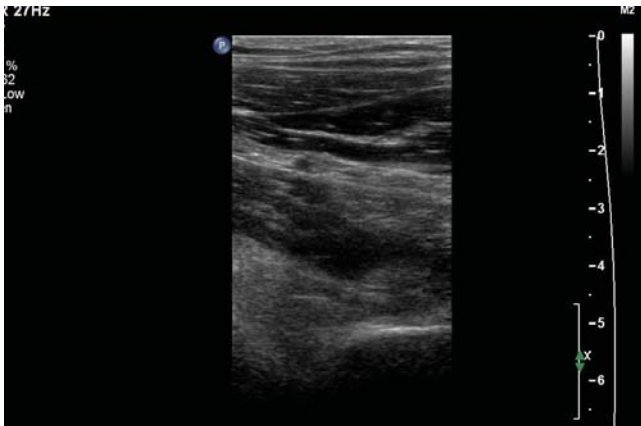

Fig. 7: Poor image of the insertion site of the iliopsoas due to physical limitation described.

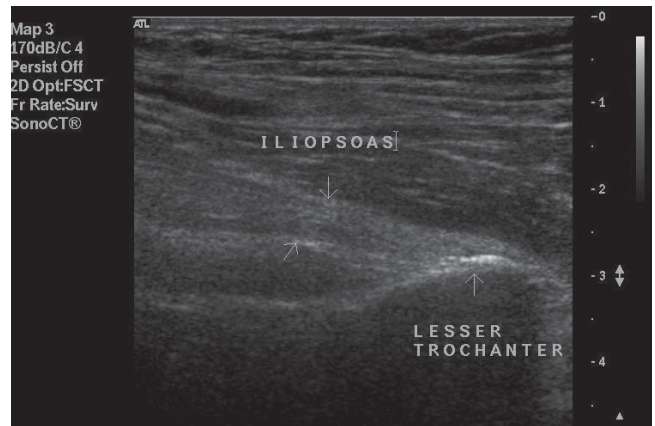


Fig. 8: Lesser trochanter is easily identified in this scan plane.

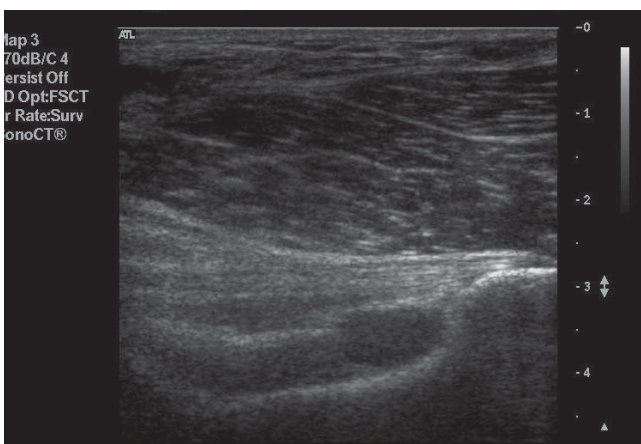


Fig. 9: Heel and toe transducer used to achieve a scan plane perpendicular to the direction of the iliopsoas tendon fibres.

Step by step approach to imaging the iliopsoas tendon insertion

- 1) Scan the hip in the standard mid sagittal plane used to evaluate the hip for a joint effusion (Fig. 5);
- 2) Slide the transducer inferiorly down the neck of the femur to just below the level of the capsule insertion on the intertrochanteric line (Fig. 6);
- 3) Abduct and externally rotate the hip slightly (only moderate abduction and external rotation is required);
- 4) Continue to scan in the sagittal plane and slide the transducer medially until the lesser trochanter is identified;
- 5) At this point the insertion site of the iliopsoas is seen, however image quality is very poor due to the previously discussed physical limitations (Fig. 7);
- 6) Slide the transducer further medially and angle laterally to achieve a scan plane through the adductor longus and

pectineus muscle bellies;

The lesser trochanter is easily identified in this scan plane and overall gain settings will have to be significantly reduced as the acoustic window improves (Fig. 8); and

- 7) Heel-and-toe the transducer to achieve a scan plane perpendicular to the direction of the iliopsoas tendon fibres (Fig. 9).

Summary

The described angled approach through the adductor longus and pectineus muscle bellies provides high quality images of the iliopsoas tendon from its insertion into the musculotendinous junction. The distal extension of the iliopsoas bursa is well visualised deep to the tendon.

Direct sonographic assessment using this technique greatly improves diagnostic confidence in imaging the difficult to visualise iliopsoas tendon insertion.

Acknowledgement

Musculoskeletal images are from the University of Washington *Musculoskeletal Atlas: A Musculoskeletal Atlas of the Human Body* by Carol Teitz, MD and Dan Graney, PhD. All rights reserved including all photographs and images. No re-use, re-distribution or commercial use without prior written permission of the authors and the University of Washington.

References

- 1 Fortin L, Belanger R. Bursitis of the iliopsoas: Four cases with pain as the only clinical indicator. *J Rheumatol* 1971; 22.
- 2 Cardinal E, Buckwatter KA, Capello WN, Duval N. US of the snapping iliopsoas tendon. *Radiology* 1996; 198 (2): 521–22.



Assessing the variable of patient positioning when examining the lower limb veins for reflux using spectral and colour Doppler ultrasound

Marion Cairnduff^A, Hans Swan^B, Brent Barton^C, AR Buckley^A

^AVancouver General Hospital Ultrasound Department, Vancouver, BC V5Z 1M9, Canada.

^BSchool of Clinical Sciences Charles Sturt Wagga Wagga, New South Wales 2678, Australia.

^CUltrasound and Diagnostic Vascular Laboratory, Vancouver General Hospital, BC V5Z 1M9, Canada.

Correspondence to Marion Cairnduff. Email mcairnduff@yahoo.com.au

Abstract

Objective: The object of this study was to determine the influence of patient position (erect and semi recumbent) on outcome diagnosis of venous reflux using spectral and colour Doppler ultrasound.

Design of study: The study design is a quantitative comparative study on patients presenting to Vancouver General Hospital Ultrasound Department for assessment of lower limb venous reflux.

Subjects and methods: A total of 71 patients were tested for valvular reflux using two techniques on one symptomatic limb. The first method was in a semi recumbent position and the second in an erect non-weight bearing position. Seven segments of the deep and superficial veins were examined using spectral and colour Doppler. Reflux was elicited using a valsalva manoeuvre and assessed by a grading technique of timed reverse flow.

Results: Mean reflux time was less in the erect position by approximately one second for the common femoral vein, greater saphenous vein, superficial femoral vein (SFV) mid, SFV distal, and popliteal vein. Results were equivalent for the SFV proximal segment. The lesser saphenous vein showed no statistical significance for equivalence between reflux times for the two positions.

Conclusions: We found that in order to accurately diagnose lower limb reflux using ultrasound and the valsalva technique, the patient does not have to be positioned erect with the exception of examining the lesser saphenous vein. By incorporating this method in scanning protocols the risk of patient and sonographer injury can be minimised.

Introduction

To date, there has been very little research examining the variable of patient position and the subsequent outcome of differences between erect and semi recumbent positioning for venous reflux assessment¹. The effect of patient position on accurate diagnosis of venous reflux in the lower limb using Doppler ultrasound has not been reliably tested. Such testing may allow the choice of better patient and sonographer safety during reflux examinations. Examining the patient in the erect position produces a major issue. The problem is that of occupational safety with respect to work injury. More than 80% of sonographers are scanning in pain and 20% of these professionals eventually experience a career ending injury². The posture of the sonographer while performing a duplex scan for lower limb venous insufficiency is very awkward if the patient stands erect. When examining the patient upright, the sonographer endures static wrist and elbow flexion. Holding the same position for a long period of time increases the risk of repetitive strain injury³. It places increased stress on operator limbs, particularly when compared to techniques where the patients are assessed in a recumbent position. Patient safety is another issue.

The protocols employed involve a valsalva manoeuvre and/or calf compression that has been shown to cause patients to feel faint when standing⁴. The lower limb of the patient often needs to be raised in order for the sonographer

to reach the area and avoid slouching. This may involve standing a patient on a raised platform or other specialised support, which in the event of a fainting episode will effectively increase the distance of falling. Specialised equipment is required, such as height adjustable chairs for the sonographer, which enable the patient and keyboard to be within reach to minimise the risk of repetitive strain injury³. It is difficult to attain optimal patient safety and sonographer workstation set up.

If a safer alternative can be proven to provide the same results as those obtained using the current technique (i.e. with patient upright) then this study would serve to help remove these problems from the workplace. This is the objective of the present study.

As previously indicated, very little research has been undertaken with regards to the research topic. No method has been standardised in eliciting and grading reflux^{1,5}. Selective and small sampling has resulted in the inability to obtain reproducible results when comparing patient positioning during ultrasound examination for valvular insufficiency. Previous studies were flawed in terms of poor sampling representation, inadequate experimental control and use of outdated imaging equipment^{6,7,8}.

The current study has been undertaken to assess the effect patient position has on outcome diagnosis for lower limb venous insufficiency using duplex Doppler. The aim is

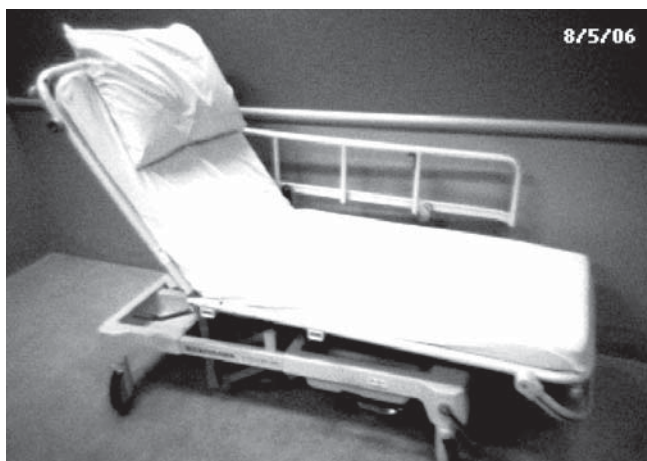

Fig. 1

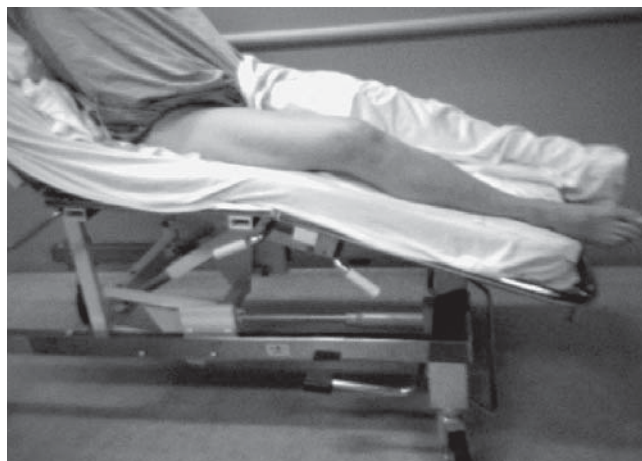


Fig. 2a

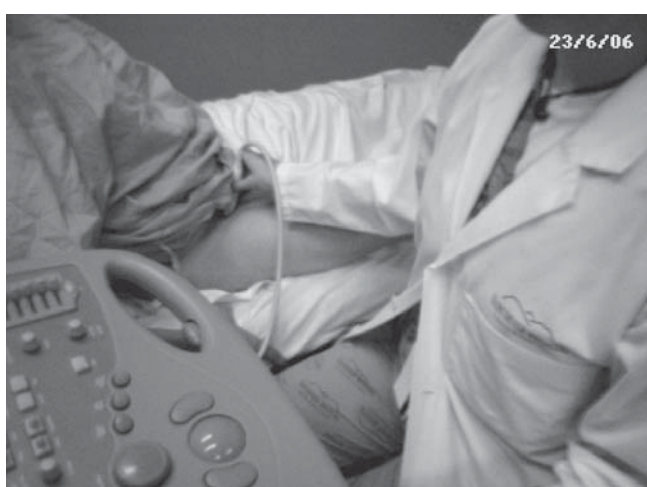

Fig. 2b

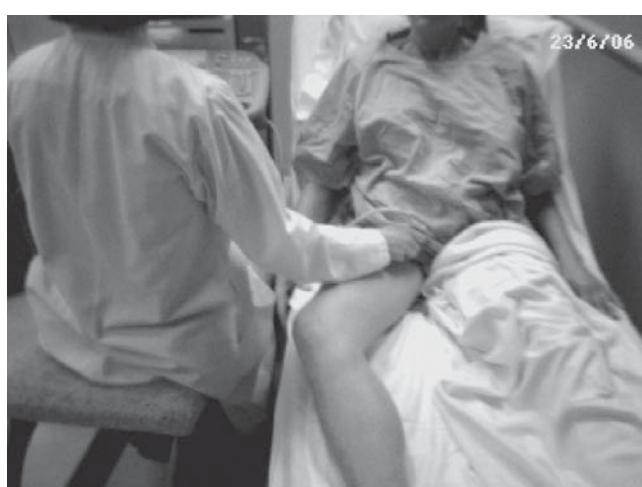

Fig. 2c

to test data for any difference and equivalence in reflux time measurements.

Materials and methods

Over a six-month period, any patient who presented to the Vancouver General Hospital ultrasound department with a request for lower limb vein assessment for venous insufficiency, was invited to participate. Seventy-one ambulatory patients were recruited. Subjects who could not stand upright for a period of 15 minutes at a session were excluded. Informed consent was obtained from all participating patients via an information sheet and by their signing of a hospital template consent form.

A quantitative comparative methodology to assess the variable of body position during an examination of the lower limb veins for venous insufficiency using ultrasound and the valsalva technique was chosen for this experiment. Detection of any differences and equivalence of measured values between the two positions, were tested.

Using an ACUSON Sequioa 512 Ultrasound system with a Linear array 6L3 transducer, venous anatomical sites were assessed for valvular reflux. Sites assessed were the common femoral vein (CFV) at the level of the valve superior to bifurcation of the greater saphenous vein (GSV), the GSV at its junction to the common femoral vein, the superficial femoral vein (SFV proximal) at the level of its valve inferior to bifurcation of common femoral vein, a mid section of superficial femoral vein (SFV mid) at mid thigh level, the

distal segment of superficial femoral vein (SFV distal) at the adductor canal, the popliteal vein (PopV) at the valve inferior to the junction of medial gastrocnemius vein, and the lesser saphenous vein (LSV) at its junction with the deep venous system, or in the event of its presence the giacomini vein.

Using B-mode to visualise anatomical sites, valvular reflux was assessed first using colour Doppler with a low velocity colour scale setting. This assisted with placement of the sample gate and flow-angle cursor for the Doppler measurement taken. A spectral Doppler sample using a Doppler angle less than 60° to the vessel wall was taken at the level of the valve during valsalva manoeuvre. To perform the valsalva manoeuvre, patients were instructed to 'breathe in, hold your breath and strain'. Measurements of reflux

Table 1: Degree of reflux

Grade 1	1–2 sec
Grade 2	2–3.5 sec
Grade 3	3.5–6 sec
Grade 4	6 sec or greater

for each segment were recorded in time (seconds) using a slow sweep speed setting. Reflux was graded according to departmental protocol for timed reflux. This is summarised in Table 1°.

Normal valve closure was accepted as 0.5 seconds of flow



Table 2: Demographics of 71 patients examined for reflux

Variable	Mean	S.D.
Age (years)	51	13
Height (cms)	167.6	9
Weight (kgs)	73.4	15.4
Body Mass Index	26.1	4.8
	<i>n</i>	%
Gender-female	58	82
History of pregnancy *	43	74
Family history of varicose veins	48	68
History of DVT	4	6
History of venous surgery or intervention	31	44
Patient able to perform examination	70	99
*13 (18%) were male		

reversal. One symptomatic leg on each patient was examined in a semi recumbent and erect non weight bearing position for comparison. The positioning methods were as follows.

Modified semi recumbent position

Using an anti-Trendelenburg examination table (Merivaara Acute Care Line Examination Table with anti-Trendelenburg option), a 15° feet down tilt was used. The head end of the table was adjusted to 60° angle to allow a person to sit upright with legs extended (Fig. 1).

The patient's leg was slightly externally rotated (refer Fig. 2a) to allow placement of the transducer by sonographer (Fig. 2b and Fig. 2c) to image the required anatomical sites.

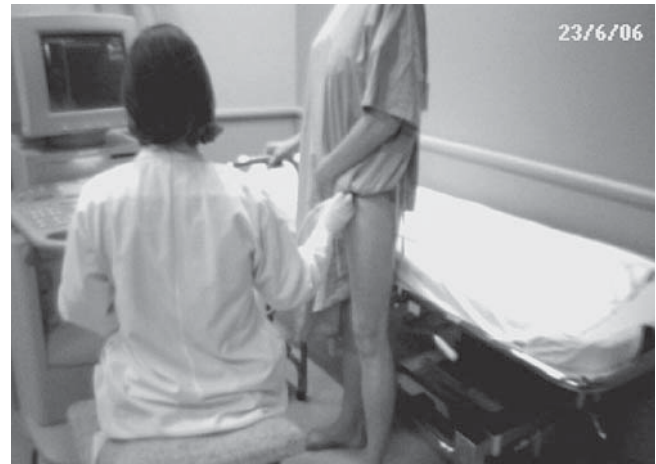Erect position

The patient was asked to stand facing the sonographer. An examination couch was positioned behind the patient so that its height was adjusted at the patient's mid thigh level. This acted as a partial support for patient stability. A step with a support handle was positioned so that the handle could be held by the patient for further stability (Fig. 3).

For examination of the lower veins and depending on patient height, some were asked to step up onto the platform. This minimised occupational strain by allowing a more optimal ergonomic position for transducer placement by the sonographer when examining lower veins. Participants were instructed to slightly externally rotate the leg, and to gently rest the leg being examined so that it was non-weight bearing. The handle and bed behind the patient allowed support onto the leg not being examined so that the weight was distributed onto this limb. Effectively, the limb being assessed for venous insufficiency was thus non-weight bearing.

A second support person was in the examination room to monitor the patient while being examined in the erect position. It was the role of the support person to ensure patient and sonographer safety in the event of a vasovagal episode. For example if the patient appeared to become unsteady the support person would intervene and assist the patient onto the examination bed to recover. The support person was a sonographer or in some cases an aid, depending on who was available at the time of examination.

The sonographer sat on a z-type height adjustable chair with knee support while examining the patient. This prevented slouching and assisted examination of the patient in the upright position by allowing the sonographer to attain

**Fig. 3**

closer proximity to the patient, thus avoiding strain due to extended limb leverage.

Statistical analysis

Initially we conducted a sample size analysis to help design our study. We chose type I error to be 0.05, statistical power to be 0.8 and assumed that 70% of measurements would be equal. We defined our range of equivalence to be 0.25 to 4 (ratio of proportion of stand > semi recumbent measured reflux times to proportion of stand < semi recumbent measured reflux times). These criteria gave a sample size of 70. For each anatomical site, the difference in measured reflux time was calculated by subtracting the standing from the semi recumbent readings. The frequency of occurrence of the differences in reflux time measurement was tabulated and expressed as a percentage. The data were tested twice, first for equivalence of results obtained by the two methods (i.e. erect v. semi recumbent) and then we estimated the differences of measured reflux time between the two methods. A non-parametric test was used to test the significance of equivalence between the two methods, that is, to test the hypothesis that there is evidence to support that the two methods are the same. Because the data can be expressed on the ordinal scale, the sign test was selected as a testing method. It was found that for only one venous location, the testing did not reject the hypothesis. This reflects a characteristic of the data that for most sites the erect and semi recumbent measurements are not equivalent.

From the data, it was further observed that for most venous sites, there was a higher percentage of occurrence of the reflux times in the erect position being less than that obtained in the semi recumbent position, than the other way round. This, therefore, reflected an unexpected hypothesis that there is a difference in recorded values between the two methods. In response to this unexpected trend, a second parametric test was performed on the same data. Erect and semi recumbent mean frequencies were compared via a paired *t*-test where the hypothesis being tested was that the mean reflux times are not the same. In all tests *P* value of <0.05 was defined as significant. We also computed 95% confidence intervals to estimate the magnitude of the difference between the two methods.

Results

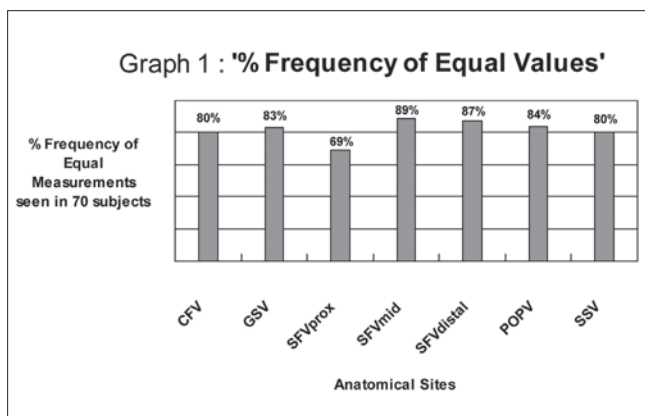
Fifty-eight female and 13 male patients participated in the study. Table 2 summarises patient demographics

Table 3: Frequency % of measured difference between standing and reverse semi recumbent positions in 71 patients.

Anatomical site	Stand < Reverse		Equal		Stand > Reverse		P-value*
	n	%	n	%	n	%	
CFV	12	17	57	80	2	3	0.07
GSV	11	16	59	83	1	1	0.11
SFV PROX	15	21	49	69	7	10	0.01*
SFV MID	8	11	63	89	0	0	0.23
SFV DISTAL	8	11	62	87	1	1	0.19
POP V**	11	16	58	84	0	0	0.13
SSV**	6	9	59	86	4	6	0.16

*P-value from sign-test for equivalence;

**Two frequencies missing



including age, height, weight, body mass index and patient history recorded at the time of examination for the population sample.

The mean values for patient age were 51 years and body mass index (BMI) of 26.1. 74% of women who presented for the study had at least one previous pregnancy. A family history link was present for 68% of patients presenting and 44% had presented with recurrence of varicose veins or insufficiency symptoms post surgical intervention. Only one participant could not complete the examination due to a fainting episode. Another patient did endure a similar episode but was able to complete the examination after a period of rest.

The number of readings where reflux time measurements for the two positions were equal ranged from 69–89%.

Graph 1 summarises the frequency percentage of equal reflux time readings observed at each anatomical site.

SFV proximal had the lowest count of equal values between the two methods at 69% while the mid section SFV reading had the highest. Table 3 summarises the individual frequencies for each anatomical site. Table 3 shows the frequency of occurrence of reflux times being observed as equal, standing reflux time less than reverse, standing reflux time greater than reverse and corresponding P-values from sign test for equivalence.

Overall, it is evident that where there is a difference in measured reflux time, a higher frequency is observed where the erect position reflux times are less in comparison to those measured with the semi recumbent technique. Most measurements in the erect position were less than the semi recumbent for the same location.

For example, refer GSV frequency stand < reverse =

16%, and erect > reverse = 1%. This is consistent with all locations except LSV where the variation of differences is not so dissimilar. Here, stand < reverse = 9% and stand > reverse = 6%.

When testing for equivalence, the data show statistical significance only for the proximal SFV, when using statistical power 0.8. None of the other sites show significance. Therefore there is not sufficient evidence to support that the methods are equivalent except when examining the proximal SFV. For example, there was no significance seen for the LSV readings. Table 4 shows the raw data frequency values observed for LSV.

The second test performed on the data assesses whether significant differences exist between recorded values (i.e. for erect > reverse reflux times v. erect < reverse reflux times). Results show significance between the two methods at the CFV, GSV, SFV mid, SFV distal, and Pop V. In order to understand the magnitude of the difference, we constructed 95% confidence intervals. Table 5 summarises P values, average difference in seconds with 95% confidence intervals for mean difference (erect – semi recumbent).

Discussion

It is a common theory that in order to accurately demonstrate valvular reflux in the lower limbs with duplex ultrasound, the patient must be positioned upright^{7, 10, 11}. This enables maximum hydrostatic pressure against the valve and engorgement of veins as a result of gravity^{5, 12}. Some literature advocates that there is a need to position a patient upright in order to optimally demonstrate the abnormality seen^{5, 13, 14}. However a separate study by Goushegir, *et al.* found that visualisation of the lower limb vein anatomy was enhanced when the patient was in a semi recumbent position¹⁵.

The results of our study do not support the theories that a patient must be positioned upright. We assume that the presence of reflux is absolute in the symptomatic patient. A more accurate diagnosis is one where reflux is seen as opposed to unseen. We accept that in whatever position it is seen, its presence is real. There is no artefactual reason for a false positive reading. From this we conclude that a more accurate result in terms of diagnosis is one where a measurement has a longer reflux time. If there is a longer reflux time seen, it suggests a higher grade up to 6 seconds. Because there is an overall increase in reflux time measurements seen in the semi recumbent position, this would indicate that this method is more accurate at demonstrating reflux than the erect position.



Table 4: Raw data frequency of SSV.

Lesser Saphenous Vein Difference Time (seconds)	Frequency	%
-6	2	3
-5	2	3
-4	1	1.5
-2	1	1.5
0	59	86
1	1	1.5
2	1	1.5
4	1	1.5
6	1	1.5
Missing frequencies	2	

Table 5: 95% confidence intervals for mean difference (erect – semi recumbent)

Those marked with * are reflux times showing statistical difference where $P < 0.05$.

Anatomical Site	Mean time difference (sec)	95% CI	P-value
CFV_diff	-0.39437	-0.77,-0.02	0.0414*
GSV_diff	-0.50704	-0.93,-0.08	0.0201*
SFVprox_diff	-0.54930	-1.23,0.13	0.1134
SFVmid_diff	-0.49296	-0.87,-0.12	0.0103*
SFVdistal_diff	-0.49296	-0.88,0.11	0.0130*
POPV_diff	-0.71014	-1.14,-0.29	0.0014*
SSV_diff	-0.21739	-0.63,0.19	0.2909

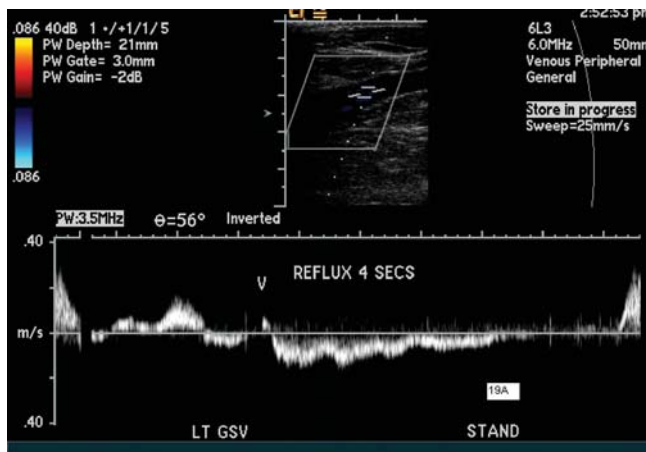


Fig. 4a: Reflux observed in erect position for patient 19A.

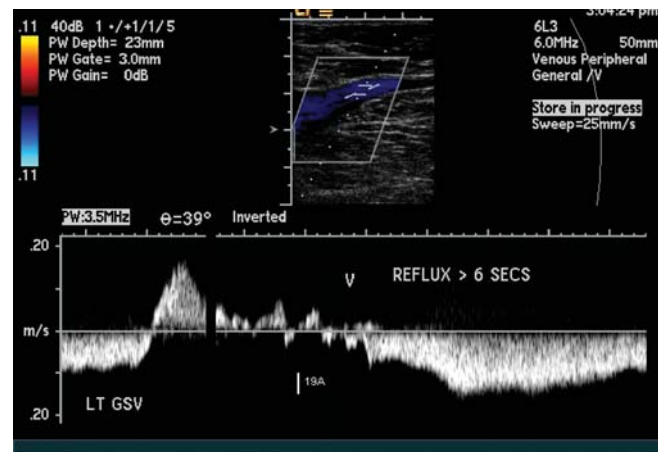


Fig. 4b: Reflux observed in semi recumbent position for patient 19A.

We demonstrated statistical significance ($P < 0.05$) that there is a difference in results for CFV, GSV, SFV mid, SFV distal, and popliteal vein sample sites between an upright and modified semi recumbent position. For these sites, the average reflux seen in the erect position was approximately 0.5–1 second less than those observed in the modified semi recumbent position. Fig. 4a and Fig. 4b is an example of a spectral trace where a difference is observed between the two positions at the GSV on the same patient. For Figs. 4a and 4b the abbreviation ‘V’ reflects the initiation of valsalva manoeuvre by the patient during the examination and therefore point of expected normal valve closure. Each bracket equals one second on the spectral time axis using a slow sweep speed setting.

The SFV proximal segment values when tested for equivalence support that the two methods are equal in diagnosis of reflux ($P < 0.05$). Therefore one could not be considered better than the other.

The LSV did not demonstrate statistical significance in either testing. Table 4 shows the raw data frequency distribution. Through general observation the spread of frequencies seen is somewhat similar. The number of values where stand < semi recumbent is similar to those where stand > semi recumbent. Two frequency values are absent from LSV as a result of one patient having a superficial clot, and a second patient not being able to continue the study as a result of a fainting episode. It may be postulated that if a larger sample

number had been obtained, the LSV may also support equivalence between the two positions. Further research in this area may prove beneficial in defining this point.

Previous studies demonstrated similar results for the CFV^{6,7}. The study by Van Bemmelen, *et al.*⁶ showed the reflux time seen using the valsalva technique for an erect position at the CFV was less than the supine 10° semi recumbent position. It is unclear in the results as to the extent that valsalva was used in the experiment as there is no comment on the comparative values seen for the other anatomical sites investigated. A hybrid of techniques was used to induce reflux in the semi recumbent position. Perhaps valsalva was only compared for the CFV. Masuda, *et al.* examined valsalva techniques in erect and semi recumbent positions and found that the semi recumbent position produced higher velocities as well as longer reflux times except for the popliteal vein⁷. In the Masuda, *et al.* study, the popliteal vein did not demonstrate statistical significance in the difference in these parameters. This may be a result of a small sample size of 30 being used and hence a low statistical power used. Another possible reason for this could be the different semi recumbent position used in the test. Previous studies have the patients supine in a reverse tilt, where as in our study we sit the patient’s upper torso upright in a sitting position. This upright torso position may further maximise the effect of blood pooling in the lower limbs thus attaining adequate hydrostatic pressure against the valves. In previous

studies the short saphenous vein was not examined^{6,7}. These studies are also limited by the antiquated equipment used and the fact that the sample selection is not representative of a realistic clinical situation. Van Bemmelen, *et al.*⁶ selected 32 healthy volunteers to participate, while Masuda, *et al.*⁷ selected 19 patients with clinical CVI and the other 11 were also normal healthy volunteers.

We believe our method for sample selection is representative of the population presenting to our department. Predisposing factors to venous insufficiency include history of previous DVT, obesity, genetic factors and the number of pregnancies¹⁶. In our sample, BMI values ranged from a minimum of 18.4 to 45 with a mean of 26.1. The BMI range of 25–29.9 is categorised as overweight and over 30 as obese^{17,18}. Of our patients, 44% had previous intervention such as venous ligation, sclerosing and stripping and were presenting with recurrence. These demographics are consistent with the expected influences of obesity on CVI and clinical presentations¹⁹. Most of the patients presented were female and 61% of those suffered from varicose veins as a result of pregnancy. Genetic factors or strong family history of varicose veins were recorded in 68% of our participants.

Our results show a consistent difference between the two positions for CFV, SFV mid, distal and popliteal vein and equivalence at SFV prox. The average difference ranged from approximately 0.5 to almost 1 sec. The impact of this observed difference in the clinical setting is questionable. According to the grading method used and its correlation to clinical symptoms a difference of one second will not have a great impact on the outcome diagnosis of venous reflux. This is because a patients' management is unlikely to be affected by this. Methods used to grade reflux in lower limbs vary^{11,5,13,20,21}. The clinical manifestations of CVI and the extent of reflux diagnosed with ultrasound does suggest a strong association, however lack of consistent grading and reporting methods in studies have not provided the evidence to support definitively one grading method over another²². Ultrasound is useful for providing information about the anatomy and presence of reflux in the deep and superficial venous systems¹¹. The outcome intervention undertaken by a treating vascular surgeon or other physician is dependant on the clinical signs and severity of CVI the patient is experiencing, and whether the reflux is located in the deep and or superficial system⁴. Classifications of CVI and correlation with grading duplex ultrasound methods are yet to be clearly substantiated^{4,11}. Ultrasound is useful in mapping and locating areas of venous reflux that is crucial to patient management⁴. The grading of venous reflux using Doppler ultrasound is not necessarily useful in determining outcome patient management. For example the information required by the treating physician to make a clinical decision is the mere presence of reflux at a certain valve or anatomical site²³, not whether reflux is seen for 3 or greater than 6 sec. Research in examining the correlation of Doppler ultrasound grading techniques and patient management outcomes for CVI would be useful in helping to facilitate its true necessity and standardisation in the clinical setting.

Patient comfort may be an explanation for improved results seen in the modified semi recumbent position. The valsalva manoeuvre is dependant on a cooperative patient^{5,22}. The patient is in a more stable and comfortable position when semi-recumbent as opposed to erect, therefore they

are able to perform the valsalva manoeuvre easily, providing longer reflux time measurements in the semi recumbent position. Only one person recruited for participation in the present study could not complete the test as a result of inability to continue. This was not due to an inability to perform valsalva but rather a vasovagal episode experienced while performing the manoeuvre.

Conclusion

Our results support that, in order to accurately diagnose lower limb reflux using ultrasound, the patient does not have to be positioned erect with the exception of examining the LSV. Using a technique where a patient is positioned in a semi recumbent manner provides mostly unchanged if not improved results by producing longer reflux time measurements for diagnosing venous incompetence in the lower limbs using valsalva manoeuvre. The semi recumbent position gives a statistically significant longer reflux time that is advantageous because identification of the presence of reflux is clinically important for patient treatment and management of venous insufficiency. Shorter reflux times that may have gone unnoticed in the erect position are better recognised in the semi recumbent position. A semi recumbent position is safer for the patient because of the associated risk of fainting while undergoing examination to assess venous insufficiency. By developing a scanning protocol whereby the patient is in a semi recumbent position, the sonographer is also able to perform duties that lower the risk of occupational injury.

Acknowledgments

I would like to acknowledge the assistance of Lisa Kuramoto MSc Statistical Analyst/Consultant Centre for Clinical Epidemiology and Evaluation Vancouver Coastal Health Research Institute.

References

- 1 Sarin S, Sommerville K, Farrah J, Scurr JH, Coleridge-Smith PD. Duplex ultrasonography for assessment of venous valvular function of the lower limb. *Br J Surg* 1994; 81: 1591–95.
- 2 2003 Consensus Conference on Work-Related Musculoskeletal Disorders in Sonography. Society of Diagnostic Medical Sonography 2003.
- 3 Massachusetts Institute of Technology: Information Page; 1999. Available online at www.web.mit.edu/atic/www/rsi/mitrsi.htm [verified May 2007].
- 4 Ruckley CV, Evans CJ, Allan P, Lee AJ, Fowkes GR. Chronic venous insufficiency: clinical and duplex correlations. The Edinburgh Vein Study of Venous Disorders in the General Population. *J Vasc Surg* 2002; 36: 520–25.
- 5 Allan P. Role of Ultrasound in the Assessment of Chronic Venous Insufficiency. *Ultrasound Quarterly* 2001; 17: 3–10.
- 6 Van Bemmelen PS, Bedford G, Beach K, Strandness DE. Quantitative segmental evaluation of venous valvular reflux with duplex ultrasound scanning. *J Vasc Surg* 1989; 10: 425–31.
- 7 Masuda E, Kistner RL, Eklof B. Prospective study of duplex scanning for venous reflux: Comparison of valsalva and pneumatic cuff techniques in the reverse Trendelenburg and standing positions. *J Vasc Surg* 1994; 20: 711–20.
- 8 Leonhardt C. Spectral colour doppler evaluation of venous reflux: A comparison of two exam techniques Ultrasound Department Vancouver General Hospital pilot study 2000.
- 9 Venous Reflux Study Protocol. Vancouver General Hospital Ultrasound Department, 2004.
- 10 Khilnani NM, Min RJ. Interventional radiology strategies treat venous



- insufficiency. Diagnostic Imaging.com; 2002. Available online at www.dimag.com/cme/articles/013.shtml [verified May 2007].
- 11 Welch H, Young C, Semegran A, Iafrazi M, Mackay W, O'Donnell T. Duplex assessment of venous reflux and chronic venous insufficiency: the significance of deep venous reflux. *J Vasc Surg* 1996; 24: 755–62.
 - 12 Rodriquez JH, Ballard JL, Rouse GA, DeLange M. Venous Imaging for Reflux Using Duplex Ultrasonography. *J Diag Med Sonog* 1998; 14: 9–13.
 - 13 Zwiebel WJ, Priest DL. Chronic venous insufficiency, varicose veins and saphenous vein mapping. In: Introduction to Vascular Ultrasonography 3rd Ed. Philadelphia: WB Saunders Company; 1992.
 - 14 Min RJ, Khilnani N, Golia, Piyush. Duplex ultrasound evaluation of lower extremity venous insufficiency. *J Vasc Interventional Radiol* 2003; 14: 1233–41.
 - 15 Goushegir G, Amizadeh S, Thelesius O. Tilting enhances visualization of lower extremity veins with duplex colour flow imaging. *Int Angiol* 1995; 14: 395–95.
 - 16 NSW Health, Australian Government web site; 2004. Available online at: www.health.nsw.gov.au/topics/varicose.html.
 - 17 The National Heart, Lung, and Blood Institute (NHLBI) web site; 2003. Available online at: nhlbisupport.com/bmi/bmi-m.htm
 - 18 World Health Organisation. Obesity and Overweight; 2006. Available online at: <http://www.who.int/dietphysicalactivity/publications/facts/obesity/en> [verified May 2007].
 - 19 Danielsson G, Eklof B, Gradinetti A, Kistner R. The influence of obesity on chronic venous disease. *Vasc Endovasc Surg* 2002; 36: 271–76.
 - 20 Baldt MM, Bohler K, Zontsich T, Bankier AA, Breitenseher M, Schneider B, Mostbeck GH. Preoperative imaging of lower extremity varicose veins: colour coded duplex sonography or venography? *J Ultrasound Med* 1996; 15: 143–54.
 - 21 Giatini D, Torem S, Pery M, Kaftori J. Image-directed Doppler ultrasound in the diagnosis of lower-limb venous insufficiency. *J Clin Ultrasound* 1994; 22: 291–97.
 - 22 Nicolaides AN. Investigation of chronic venous insufficiency – a consensus statement. *Circulation* 2000; 102: 126–63.
 - 23 Tibbs DJ. Venous disorders, vascular malformations, and chronic ulceration in the lower limbs; 2002. Available online at http://med-lib.ru/english/oxford/ven_disord.shtml [verified May 2007].
-

Sonography – the emergence of a profession

Lynette Hassall

Australian Institute of Ultrasound, Mermaid Beach, Queensland 4218, Australia
Correspondence to Lynette Hassall. Email lynette@aiu.edu.au

Abstract

This paper discusses the history of ultrasound, the emergence of sonography as a profession and the title 'sonographer' as a professional role. The education of sonographers in Australia is also discussed briefly.

Introduction

I have chosen to research this topic as history provides the background for the development of the profession as it is today.

This paper will endeavour to describe the process by which sonography has emerged as a profession and the issues which still confront the profession today. In writing this paper, I have found great difficulty in obtaining references, reflecting the dearth of information on this subject within the literature. There have been a number of articles reflecting the development of sonography and the history of ultrasound as a technical subject, but little has been written about the teaching and educational developments that accompanied the research and early development of the practice of ultrasound.

What is a profession?

'A profession is a self disciplined group of individuals who hold themselves out to the public as possessing a special skill derived from training or education and who are prepared to exercise that skill primarily in the interests of others.'

This quote is taken from an article written by David Penington and is a quote from Judge Peter Wright of the High Court of Ontario in 1951, the quote is an elegant description of what a profession entails¹. Another very famous quote (within the ultrasound community) from Dr William Garrett (obstetrician) observes that sonographers have a 'wide decisional latitude' compared to other imaging professionals², and describes the increased responsibilities which a sonographer bears. These added responsibilities are the reason for sonographers' increased initial training and ongoing learning throughout their careers

A brief history

The use of medical ultrasound grew out of the sound navigation ranging (SONAR) devices that originated during the First World War, and was further developed during the Second World War. Research was conducted in many countries – America, the United Kingdom, Europe, Japan and in Australia.

In Australia, in 1955 the National Health and Medical Research Council set up an Ultrasonics Committee to inquire into the control and use of ultrasound physiotherapy equipment, the director of the Commonwealth Acoustic Laboratories (CAL), Norman Murray, was appointed Chairman³.

In 1956, in Scotland, ultrasound was used to study ovarian cysts and in Sweden ultrasound was used to study valve motion and contractility of the heart. In 1956, research on Doppler techniques to study blood flow was conducted in Washington⁴.

In 1958, Murray recommended that the CAL undertake

research into ultrasound in Australia. Due to this recommendation, in 1959, George Kossoff, with William Garrett, an obstetrician, began the Ultrasonics Research section to research the clinical applications of the newly developed ultrasound techniques. This institute was unique in that research projects were interdisciplinary in nature – initiated by engineers and physicists, with clinicians evaluating the advances. Murray also adopted the policy that 'all equipment was to be evaluated in hospitals to determine the clinical usefulness of the new technology'⁵. On 11th May 1962, the first Australian obstetrics examination was performed at the Royal Hospital for Women, Paddington, Sydney by engineer David E Robinson and William J Garrett, an obstetrician. In June 1962, George Kossoff presented examples of the study at a symposium held at the University of Illinois, USA.

By 1969, the team at the Ultrasonics Institute had developed grey-scale imaging and were trialling obstetric, eye and breast ultrasound machines in 1970. In 1974, due to the development of the scan converter, manually driven contact scanners became commercially available within Australia⁶.

The first training was technical and in order to obtain an image with ultrasound contact scanners (1972), technique was critical. The persons operating the ultrasound contact scanner had to perform the panoramic scan with a perfectly smooth motion, which had to be scanned in 17 seconds. The first sonographer training was undertaken by scanning in rhythm with a metronome and timed by a stopwatch until the technique was mastered⁷. The researchers who developed the techniques were also the main operators of the machines in Australia at this time.

United States professional development

In the USA the people operating the ultrasound machines were known as 'ultrasound technical specialists' and in 1969, six technical specialists wrote a proposal suggesting the formation of a professional society for those people performing ultrasound examinations. This led to the creation of the first professional society for sonographers on 12th October 1970, when the American Society of Ultrasound Technical Specialists (ASUTS) was formed⁸. The founding of this society occurred very early in the development of clinical acceptance of diagnostic ultrasound, as, prior to this, most of the technical specialists were conducting research, not diagnostic procedures.

It was suggested at this stage that appropriate training programs for technicians should be instituted and two approaches were suggested by ASUTS. Both approaches



were related to the x-ray technician training, at this time set up more as apprenticeships with practical work and study in addition – one suggestion was to include ultrasound as part of the x-ray technicians curriculum, the other was to add a post-graduate year after completion of the x-ray course. At the time, neither suggestion was implemented. The reasons for this non-implementation are unclear in the literature. I can only surmise that it was thought to be unnecessary as the ultrasound operators were also researchers, developing the techniques and learning as they went along.

If either of these suggestions had been implemented at this early stage, the history of education and acceptance within the medical and administrative fields would have been very different. If sonography training had been added to the radiography course, there would have been a number of outcomes; all radiographers would have been sonographers, and no separate profession would have developed. Further, no other health professionals would have been accepted into sonography, as the training would have been an integral part of the radiography course, so all sonographers would have been radiographers.

The terminology was also important to the early development of the role of the sonographer. The main issue was semantic and the term ‘technical specialist’⁹ was used for the first sonographers in America because the American Medical Association (AMA) defined a technician as someone with six weeks to six months education beyond high school. The term technical specialist was devised to alter the perceptions of the medical specialists and alert them to the fact that sonographers were a separate profession and were dedicated to ensuring high research and educational standards for the profession.

By 1955, a consensus had been achieved and the term ‘ultrasonography’ was used to define the diagnostic procedure, ‘ultrasonograms’ were the images recorded and ‘ultrasonographers’ were the persons who performed the procedure. This was shortened to ‘sonography’, ‘sonograms’ and ‘sonographers’ and in 1974 sonography was recognised as a separate profession in the USA by the AMA¹⁰.

In contrast, the United States Department of Labour only classified the diagnostic medical sonographer as a separate occupation in the 2002–2003 edition of the Occupational Handbook.

A point of interest to note is that ‘ultrasonography’ is now used as the sole MeSH keyword for the subject in Medline Indexes¹¹.

In 1969, a working committee was created by the ‘Societas Internationalis pro Diagnostica in Ophthalmologia’ (SIDO) to develop an international non-profit scientific organisation with specific focus on diagnostic ultrasound. The members of this committee included the Chairman, Dr Vleiger, Netherlands, Dr Brown, USA, Dr Wagai, Japan, Dr Oksale, Finland, Dr Kossoff Australia, and Dr White USA. This was the beginning of the World Federation for Ultrasound in Medicine and Biology (WFUMB).

The constitution was developed in 1973, and Dr Baum, an ophthalmologist and Past President of the American Institute for Ultrasound in Medicine (AIUM), became president. The first recorded World Congress took place in 1976¹². This society still holds large world congresses dedicated to showcasing the latest research or developments within the field of ultrasound.

Vocational training in Australia

Because the first sonographers were involved in research and developing the techniques involved with the new technology, the training was technical in nature and researchers and engineers were the first to use the techniques. In 1962, CAL employed a midwife to assist Kossoff, Garrett and Robinson in their initial bistable obstetrics research¹³.

The first obstetric sonographer, Claire State, was employed by the Royal Hospital for Women, Sydney in 1970. She was involved initially in obstetrics research and then branched out into paediatric clinical trials. At this time ultrasound was being performed in the hospitals only on experimental models built at the CAL.

When the ultrasound machines were introduced commercially, the machines were placed in x-ray departments. The early companies who sold the new technology also provided training for the technicians who were going to use the machines. Often only a couple of days’ training was provided and the x-ray technician was then left to operate the new ultrasound machine¹⁴. This minimal training provided by the company was often the only way to obtain a sale, as there were no trained personnel available for hire at the time. This lack of training in the use of ultrasound was of concern to the dedicated sonographers and researchers; if the new profession was to maintain its high ideals, good education and training were essential for all persons who were to operate the machines.

In the early 1970s the Ultrasonics Institute began to offer education programs for Australian and overseas doctors (but not technicians) at its location in Sydney¹⁵.

In 1971, Michelle Gallant worked with Ian McDonald, researching echocardiography applications of ultrasound. An echocardiography teaching program for cardiologists was established in 1974 at St Vincent’s Hospital Melbourne. Ian McDonald published a definitive echocardiography textbook in the mid 1970s¹⁶.

The Australasian Society for Ultrasound in Medicine (ASUM) began as the Australian Society for Ultrasound in Medicine and Biology (ASUMB), publishing its first newsletter in December 1970¹⁷ and holding its inaugural meeting in 1971. In 1976, a group of 22 Australians from ASUMB visited ultrasound units on the west coast of the USA to study the performance of ultrasound studies there and to formulate an opinion on the implications for practice in Australia. It was realised that there was a need for identification and qualification of medical practitioners performing ultrasound studies. The group also recommended that sonographers would be certified in either general or cardiac sonography. Because of the diversity of medical practitioners involved in ultrasound studies at that time (obstetricians, cardiologists, ophthalmologists and radiologists) ASUMB established its own Diploma of Diagnostic Ultrasound (DDU) for medical practitioners to ‘identify those practitioners whose training, experience and level of competence was appropriate to referral ultrasound practice’¹⁸.

In 1977, a group of sonographers attended the ASUMS meeting in Texas, holding discussions with the directors, and decided that a formal ultrasonographers group should be set up within ASUMB, and in March of 1978 the Ultrasonographers Group was formed. Its initial task was to implement education directions and programs for the sonographers. Their document *Education and Accreditation of Sonographers* was the

basis for future education programs¹⁹.

In August 1979, the Diploma of Medical Ultrasonography (DMU) Board of Examiners was established. The establishment of this board was the start of formalised recognition of ultrasound technicians in Australia²⁰. The DMU was set up to rigorously examine candidates in both academic and practical applications. However, this was a qualification that depended entirely on self-directed learning. The DMU Board would send to the candidates a subject list, and a book list, and the timetable for the examination. At this time no tuition or extra guidance was given to the candidates and it was assumed that the candidates were self-motivated and able to self-direct their study appropriately. While this style of learning suited some people, many others experienced great difficulty, due to the essentially unstructured approach.

There were two parts to the granting of the DMU. Part 1 consisted of written examination papers in (1) Physical Principles of Ultrasound and Instrumentation; and (2) Anatomy, Physiology and Pathology. The Part 2 examination required two years of clinical experience, which equates to 3000 hours of work. There were three sections to the Part 2 examination; (1) a written paper on ultrasound techniques; (2) an oral examination in two parts – technical and diagnostic; and (3) practical examination of two random patients in an ultrasound department, conducted by two examiners.

There was a 'Foundation Phase' for the DMU, which ended on 1st January 1981, where exemption from examination was granted for sonographers who could prove clinical practical experience of greater than three years prior to January 1979. A total of 22 applicants were granted this exemption, and were the teachers and advisors for the setting up of the professional standards and education²¹ for the rest of the profession, as these sonographers were the researchers and developers of the new techniques which were being examined.

In February 1980, the first oral examinations were carried out in Adelaide and Sydney, and the first Part 1 written examinations were held in May 1980, in Adelaide, Canberra, Rockhampton, Palmerston North (NZ) and Sydney

In 1985, Graduates from the Royal Melbourne Institute of Technology (RMIT) ultrasound program were granted an automatic exemption from the Part 1 Examination, and offered a modified Part 2 Examination, in order to attain professional recognition by ASUM. This meant that even though the students had obtained the Graduate Diploma in Ultrasonography, their qualifications were not recognised by the professional body without further examinations. This was a disincentive for students to attend these tertiary learning institutions as the graduate would have to pass a second set of examinations to be recognised by the professional body.

In 1986, ASUM amalgamated with the New Zealand society and the name changed to The Australasian Society for Ultrasound in Medicine.

In 1987 the Vascular DMU was inaugurated, as sonographers were beginning to specialise in vascular applications of ultrasound. The regulations for this new diploma were published in 1988 and the foundation phase, similar to the foundation phase for the general and cardiac sonographers, expired on 1st January 1991. This foundation phase recognised six sonographers.

A syllabus was published for the General, Cardiac and Vascular Diplomas in 1992. This changed the format of the examinations, because the examinable topics were separated

into Part 1 topics and Part 2 topics, with emphasis on certain areas in order to direct candidates' learning to subjects which should be known in detail²².

In 1993, an Obstetric DMU was introduced, with an appropriate syllabus, which allowed the sonographers to specialise in the obstetrics field and qualify within that speciality.

1997 saw a change in the DMU regulations to incorporate exemption protocols and 1998 saw the introduction of Recognition Certificates to the practical examiners. Instead of the oral examinations an Objective Structured Clinical Examination (OSCE) was trialled, and received a favourable reception. This format allowed the assessment of the student's clinical skill to be performed in a more objective and reproducible format which was more easily documented, with systematic marking and guidance for the student also available. This change in format allows the Australian Sonographer Accreditation Registry (ASAR) to objectively assess the DMU qualification, and to reaccredit it as appropriate.

University based education in Australia

In April 1979, NSW TAFE started the first education course for general sonographers. This course was 15 hours in duration, but later expanded to 45 hours. This was the first step towards the introduction of sonography as a tertiary academic qualification, not a vocational qualification²³.

In 1980, RMIT established a Graduate Diploma in Ultrasonography²⁴. This was the first distance tertiary academic qualification available in Australia for sonographers, but graduates from this course had to sit an abbreviated DMU to be considered 'qualified'. This was in part due to the practical nature of ultrasound, and it was considered essential for sonographers to prove themselves competent in a clinical setting, not only academically.

In 1984, due to pressure from within the profession in Queensland, the first attempt to accredit an ultrasound course at Queensland University of Technology (QUT) was made by J Whiting, and BW Thomas. This, however, was not accomplished until 1989. QUT was thought to be a logical place for the ultrasound course to be located as it was viewed internally as an extension of the existing medical radiation technologist undergraduate program. The first intake was in July 1989 and consisted of approximately 15 students²⁵.

In 1995, the first private practical ultrasound training institute, the Australian Institute of Ultrasound (AIU) was set up on the Gold Coast, this institution was started to provide practical training in the skills required for new sonographers, and for experienced sonographers wishing to improve or update their skills. The AIU was set up in response to the perceived need for practical training for students, as there is little time for dedicated and focused training of students by senior sonographers in the clinical environment²⁶.

Many universities within Australia, such as the University of South Australia and Charles Sturt University are now offering Graduate Diploma or Masters Course work in ultrasound. The University of Sydney, in addition, also offers certificates of specialisation in vascular and cardiac ultrasound. In 2000, QUT offered a Graduate Certificate in Breast Ultrasound, in response to a need within the breast imaging community (mainly Breast Screen Queensland) and in 2002, a dedicated



cardiac ultrasound course was offered.

Monash University is the latest university to offer an ultrasound course, and this was offered in 2002²⁷.

Many issues arise with these courses in the Universities²⁸. These were discussed at the September 2005 ASUM Conference. Practical assessment of student sonographers is critical and, although guidelines are issued, there is the question of reproducibility of results and comparison of competency or criterion referenced assessment between one examiner and another, and between one university and another. The standards of courses between universities are monitored by the ASAR, but the issues of quality control and equity remain²⁹.

Another issue is the increase in the number and complexity of ultrasound examinations, and the requirement of the Commonwealth Department of Health and Aged Care (DHAC) for formal accreditation of sonographers. This requirement necessitates that sonographers obtain accreditation at the beginning of their career, while they are still inexperienced students. While this increase in regulation and responsibility has occurred, there has been a significant reduction of funding to the higher education sector, with a decrease in funding for courses and university staffing levels. This leads to an increased workload on academic sonographers concurrent with an increased expectation and need for training of students who are less experienced practically, and often only fulfill the very minimum requirements for admission to the university courses³⁰. Due to the expectation that sonographers in academic positions will increase their own skills and education by studying for Masters and PhDs as well as maintaining their own clinical skills, the universities are experiencing great difficulties in both attracting and retaining suitably experienced sonographers. If this is taken to its natural conclusion, with experienced university-based sonographers leaving, there is the potential for existing courses to become non-viable, or to have less experienced and less skilled, but more academically able, sonographers teaching the students.

Recognition within Australia

In 1983, the New Zealand Government established the DMU as the standard for registration as a sonographer in that country. This meant that ASUM had an internationally recognised qualification which was not recognised nationally³¹.

At present, the Ministers of Health in New South Wales, Tasmania and Western Australia recognise the DMU but, as yet, the other states do not. The Queensland Department of Health has not acknowledged the profession of sonography as a separate profession to radiography. This impacts negatively on the wages and conditions of sonographers working in the public health system, as the wages are equivalent to a radiographer's wage. Sonographers who are employed in the private sector have been recognised as a profession and paid accordingly for many years, due mainly to the shortage of sonographers and the increasing demand for the use of ultrasound for diagnosis.

The Federal Government has recognised sonography as a profession due to the DHAC regulations which require 'suitably qualified and accredited' sonographers to perform medical ultrasound studies in order for the patient to be eligible for Medicare rebates³². It is a bizarre dichotomy – the Federal Government recognises sonographers Australia wide, but some individual state governments do not.

Regulation

A major impact on the development of sonography as a profession occurred in the early 1990s when sonographers were accepted as full members of ASUM. Prior to this, sonographers were associate members and, as such, not entitled to a vote. This was a contentious issue for ASUM as the full members were all physicians or researchers and tended to disparage the accomplishments of the sonographers. Intense lobbying by many of the sonographers was needed to convince the members of ASUM that sonographers were worthy of inclusion as full members, and the 1994 Annual General Meeting, at which this vote was taken, was the largest ASUM had seen³³. This vote meant that sonographers were accepted and acknowledged as full members of their own professional body, and was a potent argument in the recognition of ultrasound as a profession.

In 1990, the DMU Board of Examiners met to discuss accreditation of ultrasound qualifications offered by Australian universities. Representatives from the Australian Sonographers Association (ASA), the Australian Institute of Radiography (AIR) and the Ultrasonographers Group of ASUM had discussions that led to the formation of ASUM's working committee, the Ultrasonographers Qualification Accreditation Working Party. This in turn led to the formation of the Ultrasonographers Qualification Accreditation Committee (UQAC) which recommended an Accreditation Registry be set up, and the Australian Sonographer Accreditation Registry (ASAR) was established in October 1994. The ASAR has established criteria to assess and judge academic programs in both Australia and New Zealand. The registry also has an important function in that it accredits ultrasound training programs, and reassesses and reaccredits these programs on a regular basis (usually a five year period)³⁴. The ASAR also maintains a registry of accredited and student sonographers and monitors and records the continuing professional development (CPD) activities of members. Due to the accreditation of academic programs, graduates from the universities who had not sat for the DMU could now be accredited and recognised within the profession, without having to sit an abbreviated DMU exam.

Further to this accreditation, DHAC introduced the requirement that sonographers performing diagnostic ultrasound on behalf of a medical practitioner and if a Medicare rebate was to be claimed, had to be 'suitably qualified', maintain their continuing professional development and be registered with the ASAR. DHAC has sonographers enrolled on a Register of Sonographers and it is only these enrolled sonographers whose patients are able to claim a Medicare rebate for the ultrasound service³⁵. This requirement for qualification did not specify where the sonographers obtained their qualification for accreditation purposes.

Formation of the accreditation body also means that the DMU will be scrutinised by a third party on a regular basis, and must also be accredited with the ASAR.

The ASAR led to significant changes in the way the DMU was regulated, major changes were implemented from 1994–1996, with input from the ultrasound faculties from QUT, University of Queensland and Sydney University. Changes in the format of the exam itself and specific requirements for numbers of examinations performed were introduced³⁶.

The examiners for the DMU were also issued with

handbooks and were required to attend seminars and to document comments and critiques for release to the candidate. The whole DMU process became much more accountable and open to inspection and review. The introduction of the requirement for the DMU examiners to be accredited in 2004 was particularly relevant as the examiners now need to be trained and so consistency can be maintained, not only between examiners but also from year to year. Prior to this training and accreditation process, the only qualification required of the examiners was to hold a DMU, and to be willing to volunteer their time.

A significant portion of the ASAR mandate is to maintain a record of the CPD activities of the members, virtually ensuring a commitment to life-long learning within the profession.

The Australian Sonographers Association (ASA) was formed in Melbourne in 1992, in response to a perceived need for an organisation that solely represented sonographers, and the issues confronting sonographers. Its mission statement is to 'represent sonographers and raise the profile of the ultrasound profession'³⁷. ASUM was, and still is, a multidisciplinary body and represents clinicians as well as sonographers.

Conclusion

Ultrasound education in Australia developed from its early beginnings in the research and development of a new technology. Increased demands on sonographers in respect of their clinical skills, knowledge and independence has shown itself in the stringent accreditation requirements now in place and in the prevalence of the more structured ultrasound courses available in universities. These university courses were originally started due to pressure from within the profession in recognition that alternative courses to the DMU were required. The increasing popularity of the university courses proves that many students preferred a formal structure to their learning, with rigorous instruction and examination guidelines. The universities rely on support from the profession, as the student sonographers must be employed by a clinical practice in order to access the course. Clinical supervisors are expected to provide the practical training and guidance these students require to become competent sonographers. A complication of this workplace training is the increasing corporatisation of the medical profession, with greater expectations and higher patient workloads being required for the experienced sonographers, and for the student sonographers who are also expected to be contributing members of the team as quickly as possible.

The DMU is a highly regarded qualification, both in Australia and throughout the world, and offers an alternative path to accreditation for persons wishing to become sonographers. This is useful for students who are unable to attend on-campus blocks of lectures due to distance, work or family commitments, and have the ability to dedicate themselves to learning at their own pace. Due to the ASAR requirements, however, the DMU also offers preparatory classes for their candidates, which offers a more structured approach to learning.

Another benefit that the ASAR has achieved is that sonographers must be committed to lifelong learning, with maintenance of their accreditation contingent upon their achieving a specific number of CPD points each triennium. This, however, raises more questions on where these 'points' are earned.

I believe that the universities should be mindful of the lifelong learning requirements for the profession and should be offering vocational courses to qualified sonographers, not just to persons who wish to qualify in the profession.

This needs to be a focus for the future at universities across Australia and indeed could become a source of additional funding as continuing professional education (CPE) courses could be run for profit and this could subsidise the training of the students. The AIR, ASA and ASUM all offer conferences and day seminars, but this role could be enhanced by the universities, which have expertise and facilities available.

Most of the ultrasound research is now being performed in-house at various equipment manufacturers, in order to improve their equipment and therefore, sales. Very few developments have recently been achieved at universities, which appear to be content to teach entry-level courses and leave the research and development to the manufacturers. This may well reflect the funding available for research where any funding must be obtained from outside sources and it appears to me that the main requirement is that the research be financially successful.

The development of specialised DMU qualifications and the offering of breast, vascular and cardiac courses by universities, reflect the increasing specialisation within the profession, and an acknowledgement that one person cannot be competent in all aspects of sonography. These specialised qualifications also fulfill the requirement by DHAC for 'suitably qualified and accredited sonographers' to perform examinations.

In the future, sonographers aspire to take on even higher-order responsibilities with the introduction of sonographer practitioners. In the United Kingdom, sonographer practitioners work within the National Health System and issue reports on their work to the referring doctors. In Australia, we are legally constrained only to communicate our findings to the radiologist we work for and are unable to communicate our findings directly to either the patient or the referring physician.

In order for the sonographers to move forward in the profession, we need to be recognised by all state and federal governments. The lack of recognition does not impact on our professionalism and the way in which we conduct ourselves, but on the wages and respect we receive from our employers and the community. We need to insist on maintaining and strengthening the quality of sonographer education, and the quality of graduates from the universities must be maintained and improved, despite the funding and staffing difficulties involved.

Acknowledgements

Thanks to Sue Davies, AIU, for her support, criticisms and comments.

Thanks to James Hamilton, ASUM Education Officer, for assistance in locating non-digitised copies of the ASUM Newsletter.

References

- 1 Penington D. Reflections on being a medical professional in the year 2000. *ASUM Ultrasound Bulletin* 2000; 3 (4): 17–20.
- 2 Garrett W. Quoted by Griffiths K. *ASUM Newsletter* 1989; 2 (5): 7.
- 3 Kossoff G. How Research into medical ultrasound began in Australia.



- ASUM Ultrasound Bulletin* 2000; 3 (4): 8.
- 4 Baker J. The History of sonographers. *J Ultrasound Med* 2005; 24: 1–2.
 - 5 Kossoff G. How research into medical ultrasound began in Australia. *ASUM Ultrasound Bulletin* 2000; 3 (4): 8.
 - 6 Griffiths K. An historical look at ultrasound as an Australian innovation on the occasion of the ultrasound stamp issued by Australia Post – 18 May 2004. *ASUM Ultrasound Bulletin* 2004; 7 (3): 22.
 - 7 Griffiths K. An historical look at ultrasound as an Australian innovation on the occasion of the ultrasound stamp issued by Australia Post – 18 May 2004. *ASUM Ultrasound Bulletin* 2004; 7 (3): 23.
 - 8 Valente C, Wagner S. History of the American Institute of Ultrasound in Medicine. *J Ultrasound Med* 2004; 24: 131–42.
 - 9 Baker J. The History of Sonographers. *J Ultrasound Medicine* 2005; 24: 6.
 - 10 Woo J. A short history of the development of ultrasound in obstetrics and gynecology Part 1. Available online at: www.ob-ultrasound.net/history1.html [verified September 2005].
 - 11 Woo J. A short history of the development of ultrasound in obstetrics and gynecology' Part 2. Available online at: www.ob-ultrasound.net/history2.html [verified September 2005].
 - 12 Griffiths K. An historical look at ultrasound as an Australian innovation on the occasion of the ultrasound stamp issued by Australia Post – 18 May 2004. *ASUM Ultrasound Bulletin* 2004; 7 (3): 24.
 - 13 Baker J. The history of sonographers. *J Ultrasound Med* 2005; 24: 4.
 - 14 History of WFUMB. Available online at: www.wfumb.com/history.html [verified September 2005].
 - 15 Griffiths K, Tabrett M. Diploma of Medical Ultrasonography – the first 10 years. *ASUM Ultrasound Bulletin*; 2 (1): 4.
 - 16 Griffiths K and Tabrett M. Diploma of Medical Ultrasonography – the first 10 years *ASUM Ultrasound Bulletin*; 2 (1): 5.
 - 17 Woodward S. Executive's column. *ASUM Ultrasound Bulletin* 1998; 1 (1): 2.
 - 18 History of the DDU. Available online at: www.asum.com.au/ddu.html [verified September 2005].
 - 19 Griffiths K, Tabrett M. Diploma of Medical Ultrasonography – the first 10 years *ASUM Ultrasound Bulletin*; 2 (1): 5.
 - 20 Baker J. The history of sonographers. *J Ultrasound Medicine* 2005; 24: 6.
 - 21 Baker J. The History of Sonographers. *J Ultrasound Med* 2005; 24: 7.
 - 22 Mitchell J. The second decade of the Diploma of Medical Ultrasonography 1989–1999. *ASUM Ultrasound Bulletin* 1999; 2 (2): 25–7.
 - 23 Griffiths K, Tabrett M. Diploma of Medical Ultrasonography – the first 10 years' *ASUM Ultrasound Bulletin*; 2 (1): 5.
 - 24 RMIT website. Available online at: www.rmit.edu.au [verified September 2005].
 - 25 Thomas BJ. email 29/9/05 personal communication.
 - 26 Davies S. Personal Interview, Oct 1 2005.
 - 27 Personal email, Gill M. Oct 7 2005. First QUT Ultrasound course coordinator.
 - 28 Clarke J, and Gill M. University based education for sonographers – issues and challenges for the profession. Proceedings of ASUM 2005 35th Annual Scientific Meeting; 2005 Oct 1; 2005.
 - 29 Parkes J. Equity and reproducibility issues in practical assessment of student sonographers. Proceedings of ASUM 2005 35th Annual Scientific Meeting; 2005 Oct 1; 2005.
 - 30 Clarke, J, and Gill, M. University based education for sonographers – issues and challenges for the profession. Proceedings of ASUM 2005 35th Annual Scientific Meeting; 2005 Oct 1; 2005.
 - 31 Griffiths K, Tabrett M. Diploma of Medical Ultrasonography – the first 10 years. *ASUM Ultrasound Bulletin*; 2 (1): 6.
 - 32 Australian Government Department of Health and Aging – Sonographer Accreditation Policy Statement. Available online at: <http://www.health.gov.au/internet/wcms/publishing.nsf/Content/diagnosticimaging-quality.htm> [verified September 2005].
 - 33 Davies, S Personal interview, 1 October 2005
 - 34 Australian Government Department of Health and Aging – Sonographer Accreditation Policy Statement. Available online at: www.health.gov.au/internet/wcms/publishing.nsf/Content/diagnosticimaging-quality.htm [verified September 2005].
 - 35 Australian Government Department of Health and Aging – Sonographer Accreditation Policy Statement. Available online at: www.health.gov.au/internet/wcms/publishing.nsf/Content/diagnosticimaging-quality.htm [verified September 2005].
 - 36 Mitchell J 1999. The second decade of the Diploma of Medical Ultrasonography 1989–1999. *ASUM Ultrasound Bulletin* 1999; 2 (2): 25–7.
 - 37 Australian Sonographer Association Mission Statement. Available online at: www.a-s-a.com.au/mission.htm website [verified September 2005].

The prenatal imaging of thanatophoric skeletal dysplasia: a case review

Ben Micallef, David Fauchon, Ron J. Benzie

Christopher Kohlenberg Department of Perinatal Ultrasound, Nepean Hospital, University of Sydney, Penrith, New South Wales 2750, Australia.

Correspondence to Ben Micallef. Email micallb@tpg.com.au

Introduction

Thanatophoric dysplasia is defined as a fatal skeletal dysplasia. Such dysplasias are characterised by short limb bones, a narrow thorax and hypoplastic lungs. The fatal nature is due to cardiorespiratory failure secondary to the hypoplastic lungs. Thanatophoric dysplasia presents with a large skull, narrow thorax and pronounced rhizomelic dwarfism. It can be separated into two subtypes¹.

Type 1

- Large cranium;
- Prominent forehead and depressed nasal bridge;
- Narrow thorax with hypoplastic lungs (Champagne cork appearance); and

- Short and bowed long bones (telephone receiver appearance)².

Type 2

- As for Type 1 but with the addition of a cloverleaf skull, which is a trilobed appearance in the coronal plane. This is due to premature closure of the coronal and lambdoid sutures²; and
- Limbs are slightly thinner and straighter.

Other associated anomalies include holoprosencephaly, agenesis of the corpus callosum, ventriculomegaly (Fig. 3), horseshoe kidneys, hydronephrosis, congenital heart disease, radioulnar synostosis and imperforate anus².

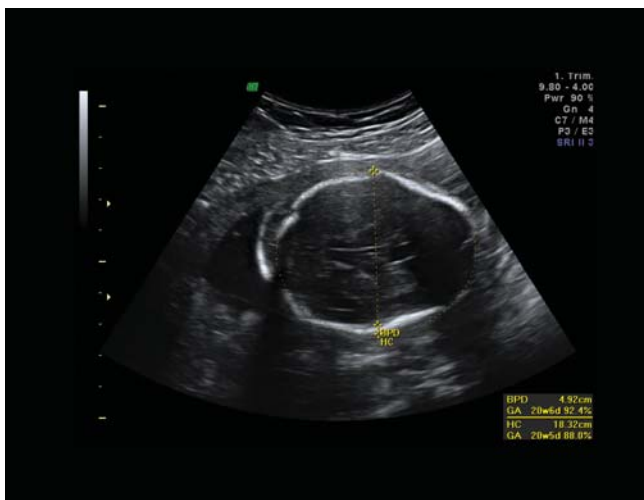

Fig 1: Axial image of the fetal head demonstrating a large HC.

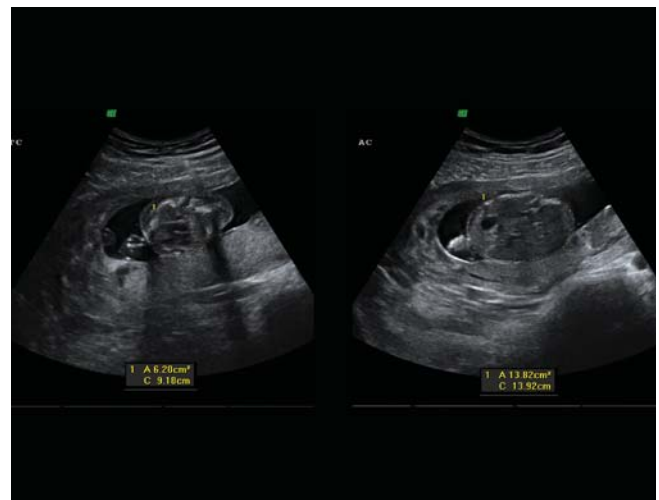

Fig 2: Axial images of fetal thorax and AC demonstrating the small TC:AC ratio.

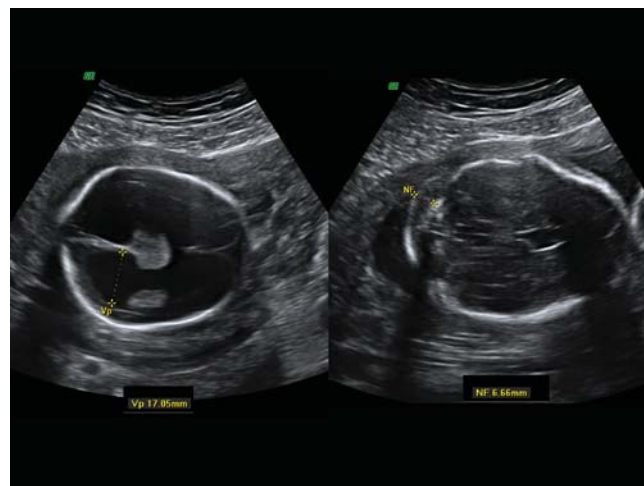

Fig 3: Axial images of the fetal head demonstrating ventriculomegaly and a thickened nuchal fold.

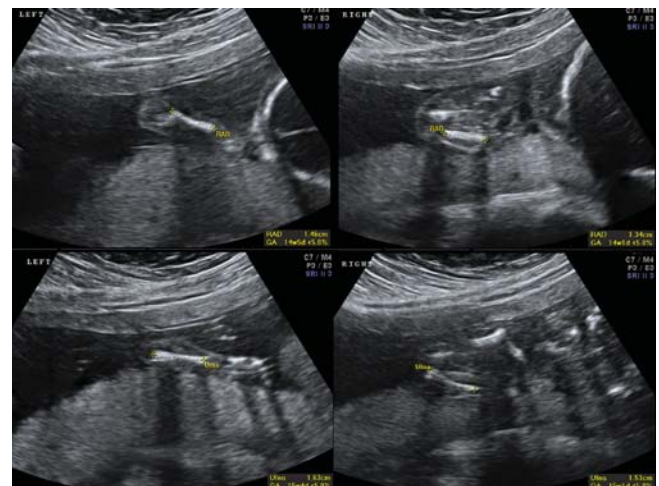


Fig 4: Shortened forearm bones.



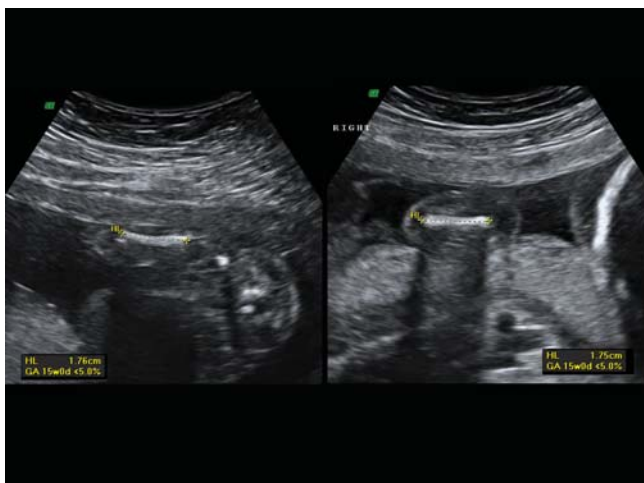

Fig 5: Short humeri.

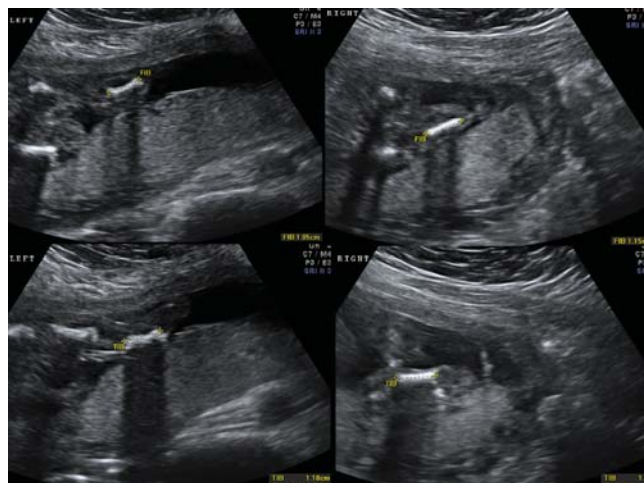


Fig 6: Shortened tibia and fibula bones.

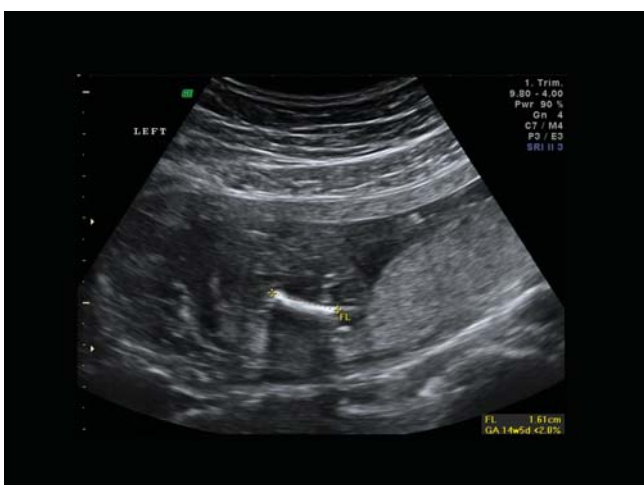

Fig 7: Short femur length.

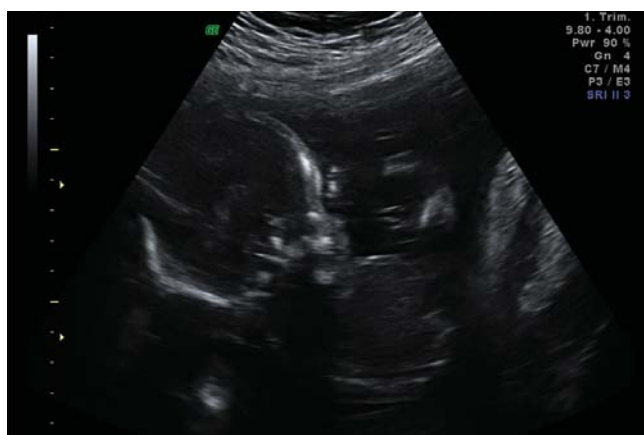

Fig 8: Frontal bossing and depressed nasal bridge.

Clinical background

A 26-year-old gravida 2 para 0 presented for a fetal anatomy scan at 19 weeks gestation where several fetal abnormalities were detected and the suggestion of skeletal dysplasia was made.

She was referred to Perinatal Ultrasound at Nepean Hospital for a second fetal anatomy scan at 19 weeks 4 days gestation. The scan revealed:

- Large HC well above the 95th percentile (Fig. 1);
- TC:AC ratio of 0.61: <math>< 0.8</math> is regarded as abnormal² (Fig. 2);
- All long bone lengths well below the 5th percentile (Figs. 4–7);
- Bilateral ventriculomegaly (Fig. 3);
- Thick nuchal fold of 6.7 mm (Fig. 3); and
- Frontal bossing and depressed nasal bridge (Fig. 8 and Fig. 10).

Discussion

Skeletal dysplasias (osteochondrodysplasias) are a group of disorders that affect the growth and development of the musculoskeletal system. There have been over 200 different subtypes reported in the literature. An Italian multicentre study during the period 1978–1981 showed the incidence of skeletal dysplasia is approximately 1:4100 including stillbirths¹. Other more recent studies have obtained similar results³.

Data from a population registry of congenital

abnormalities found that the most common skeletal dysplasias were:

- Thanatophoric dysplasia (lethal);
- Achondroplasia;
- Achondrogenesis (lethal); and
- Osteogenesis Imperfecta (Type 2 lethal)¹.

Imaging

The sonographic detection and differentiation of skeletal and limb anomalies requires a careful, thorough scan of the fetal anatomy giving extra attention to the head, spine, bony thorax, limbs and accurate biometry paying special attention to the long bones¹.

- There are four main patterns of limb shortening and these are referred to as:
- Rhizomelia: Shortening of the proximal segment (femur and humerus);
- Mesomelia: Shortening of the middle segment (radius/ulna, tib/fib)
- Acromelia: Shortening of the distal segment (hands and feet);
- Micromelia: Shortening of the entire limb (mild, mild/bowed or severe); and
- Amelia: Absence of a limb.

The diagnosis in this case could have been made with the 2D imaging alone. The 3D imaging did not offer much more to the final sonographic diagnosis. However, when counselling the parents, the 3D and 4D ultrasounds played a

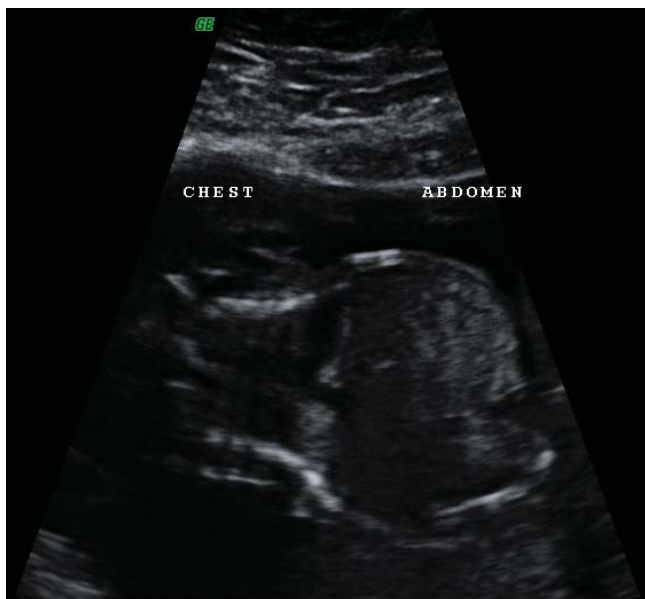


Fig 9: Coronal image of thorax and abdomen demonstrating 'Champagne Cork' appearance.

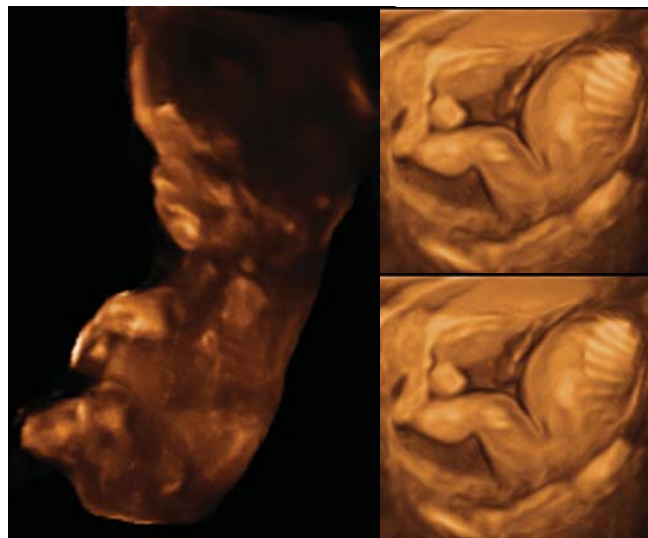


Fig. 10: 3D rendered images demonstrating frontal bossing, depressed nasal bridge and shortened limbs.

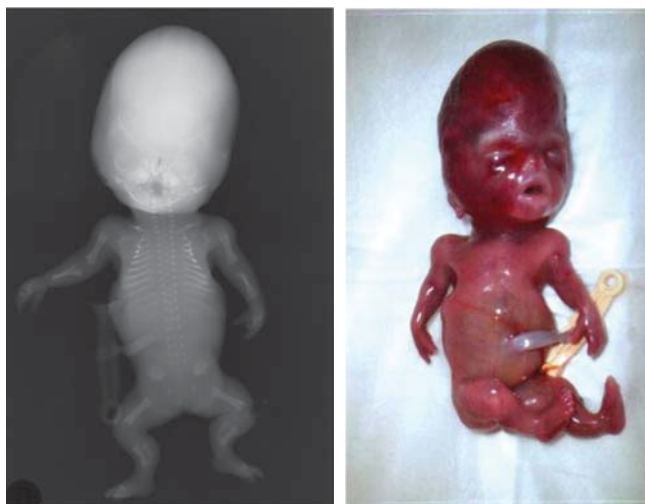


Fig.11: Post-natal radiograph and photograph.

valuable part in describing the anomalies encountered. Most patients and people with a non-sonographic background have great difficulty in comprehending 2D ultrasound images. A better understanding of both normal and abnormal surface anatomy is gained when it is illustrated by 3D ultrasound images. This enables more objective and focused counselling, and allows specialists to explain management more effectively⁴. A radiograph of the fetus was performed post termination that further strengthened the diagnosis of thanatophoric dysplasia (Fig. 11).

A recent article by Cassart, *et al.* (2007) has suggested the use of 3D CT as a complementary imaging modality in the management and diagnosis of skeletal dysplasias prenatally. Traditional orthogonal x-rays of the maternal abdomen allow visualisation of the fetal skeleton and allow identification of possible abnormalities in bone shape and size, but superposition of fetal and maternal bones can cause difficulty in visualisation.

However, 3D CT removes the maternal bones allowing full visualisation of the fetus from any angle. The difference in radiation dose is negligible when applying adequate CT imaging parameters.

Outcome

In cases of thanatophoric dysplasia and other fatal dysplasias termination is justified and often elected. In fetuses carried to term, macrocephaly can cause complications in vaginal delivery, therefore early delivery is usually advised to spare the mother of the needless risk of a caesarian section¹.

The patient and her husband were counselled in relation to genetic amniocentesis for aneuploidy and elected to proceed with the diagnostic test. The amniocentesis revealed a normal 46,XX karyotype. The patient underwent further counselling and elected to have a termination. She agreed to an autopsy, which supported the diagnosis of thanatophoric skeletal dysplasia. If the findings of Cassart, *et al.* are validated by larger studies, future cases may be more definitively diagnosed prenatally by employing 3D CT.

References

- 1 Merz E. *Ultrasound in Obstetrics and Gynaecology* 2nd Ed. New York: Thieme: 2005.
- 2 Rumack C, Wilson S, Charboneau J. *Diagnostic Ultrasound vol 1* 2nd Ed. Sydney: Mosby; 1998.
- 3 Gonclaves L, Jeanty P. Fetal biometry of skeletal dysplasias: a multicentric study. *J Ultrasound Med* 1994; 13: 977–85.
- 4 Micallef B, Fauchon D, Benzie RJ. Cornelia de Lange syndrome: the value of 3D and 4D ultrasound. *ASUM Ultrasound Bulletin* 2007; 10 (2): 33–4.
- 5 Cassart M, Massez A, Cos T, Tecco L, Thomas D, Van Regemorter N, Avni F. Contribution of three-dimensional computed tomography in the assessment of fetal skeletal dysplasia. *Ultrasound Obstet Gynecol* 2007; 29: 537–43.

Scanning the journals

Examination of the fetal heart: making a diagnosis and avoiding pitfalls

Hikoro Matsui, HM Gardiner. *Ultrasound* 2007; 15 (2): 62–67

This is a good basic practical review of fetal cardiac examination demonstrating the value of the 5 transverse as well as the oblique, short axis and sagittal views. Pitfalls in the examination are outlined. Cardiac examination is the most challenging part of the fetal anatomy scan and a short review such as this may help to increase our diagnostic accuracy.

Turning up the power: high intensity focused ultrasound (hifu) for the treatment of cancer

Gail ter Haar. *Ultrasound* 2007; 15 (2): 73–77

HIFU is becoming increasingly used in the treatment of bone, pancreatic breast and prostate cancers. More than 20 000 cancer patients have been treated and while the indications for treatment are still to be established, work from China and Korea shows promise. Whether its role in cancer treatment will be curative or palliative is not yet clear. It is interesting that therapeutic ultrasound was described 16 years before diagnostic ultrasound.

Amniotic band syndrome

Kumar M *et al.* *Ultrasound* 2007; 15 (2): 96–98

This is a case report and literature review of an anomaly whose aetiology is not clear. The range of defects associated with amniotic bands varies from amputation or constriction of limbs and digits to intracranial, facial or anterior abdominal defects.

Fortunately, most amniotic bands we see are not associated with dire outcomes but this report does remind us of the need for serial review of these cases. We have found 3D/4D can provide additional information in some.

Colour-coded duplex sonography after renal transplantation

Thalhammer C *et al.* *Ultraschall in Med.* 2007; 28: 6–27

This is a continuing education article complete with CME questions. While it is highly specialised, it does remind us of the importance of ultrasound follow up of vascular connections in the transplanted kidney.

Ultrasound of the stomach – The Euroson Lecture 2006

Gilja OH. *Ultraschall in Med.* 2007; 28: 32–39

Did you know that ultrasound can be used to study not only gastric configuration but motility, distensibility and intragastric distribution? Neither did I! And it is the only technique that can measure all aspects of gastric structure and function simultaneously.

Ultrasound Doppler of the achilles tendon before and after injection of an ultrasound contrast agent – findings in asymptomatic subjects

Koenig MJ *et al.* *Ultraschall in Med.* 2007; 28: 52056

This is worth reading. The authors concluded that Achilles tendinopathy diagnosis can be difficult. Even in normal asymptomatic patients the majority of tendons had abnormalities. Some of these may be age-related but age-stratified normal information is lacking. Even if Doppler activity is seen it is not necessarily pathological. Contrast agents were used to demonstrate intratendinous flow. But there was no consistency between ultrasound and clinical diagnosis of tendinopathy. Food for thought.

Clinical application of grey scale and colour Doppler sonography during abnormal third stage of labour

Krapp M *et al.*, *Ultraschall in Med.* 2007; 28: 63–66

Postpartum haemorrhage is still a significant cause of maternal morbidity. As the author of this German study states 'Sonography has changed obstetrical care in the past 40 years, but has not yet conquered the delivery room.'

They monitored abnormal third stage in 20 cases. As 90% of third stages are complete by 14 minutes after delivery, they started uterine scanning after that time. They had already been able to distinguish the latent, detachment and expulsive phase in normals with grey scale. With colour Doppler they could also determine whether the placenta was accreta or not and whether retained placental fragments had persistent blood flow between myometrium and placenta.

While ultrasound is used prenatally on the labour floor, there is also a place for it in the third stage of labour, it seems.

The Gleaner

Additions to the ASUM Video Library

For orders, use the order form in the Video Library Catalogue distributed with this issue or log on to www.asum.com.au

- 168 DVD The Accuracy of Ultrasound for Diagnosing Focal Lesions of the Hand and Wrist – Sharlene Teefey 2006
- 167 DVD Testicular Microlithiasis: Is it a Marker for Malignancy? – Sharlene Teef 2006
- 166 DVD Use of Ultrasound in Male Infertility – Gordon Baker 2006
- 165 DVD Tears of the Gluteal Tendons: A Surgeon's Perspective – Elton Edwards 2006
- 164 DVD Paediatric Hip Ultrasound – Cain Brockley 2006
- 163 DVD A new Method for Ultrasound Evaluation of Iliopsoas tendon insertion – Stephen Bird 2006

C2 The Role of the Sonographer

February 1996, Revised September 1999, November 2006

Introduction

Diagnostic ultrasound is used in healthcare as a diagnostic modality to confirm or exclude disease so a referring medical practitioner may institute appropriate patient management.

A sonographer is a health care professional who has undertaken an appropriate postgraduate course of practical and theoretical study specific to the practice of diagnostic ultrasound and is practising that speciality.

Ultrasound has evolved to encompass echocardiography (including transthoracic, transoesophageal, intravascular and intracardiac examinations), vascular, obstetric and gynaecological, general and musculoskeletal ultrasound, including intracavity and interventional applications.

Education

The Australasian Society for Ultrasound in Medicine (ASUM) recognises an appropriate graduate-level qualification involving a practical assessment conducted by accredited assessors, not connected with their practice or teaching institution, as the suitable qualification for a sonographer.

To maintain professional competence sonographers must maintain a high level of continuing professional development throughout their careers. ASUM recognises 50 hours of learning activity directly relevant to their practice as the minimum annual requirement.

Sonographers

The Australasian Sonographer Accreditation Registry (ASAR), in Australia, and the New Zealand Medical Registration Technologists Board (NZMRTB), in New Zealand, accredit sonographers to practice in their respective jurisdictions. The Role of the Sonographer document applies to all of these sonographers.

Sonographers are drawn from a wide range of career related backgrounds. These include medical and pure science, applied science such as diagnostic and therapeutic radiography, nuclear medicine, nursing, cardiac technology and vascular technology.

Qualifications include the Diploma of Medical Ultrasonography (DMU) awarded by the Australasian Society for Ultrasound in Medicine (ASUM), graduate qualifications in medical sonography offered by Australian and New Zealand tertiary institutions and accredited by the ASAR for practice in Australia or the NZMRTB for practice in New Zealand, and appropriate overseas qualifications.

'Sonographer' as a term to define a qualified professional

It is intended that only the fully qualified be designated Sonographer. Before completion of training, 'trainee sonographers' should work only under the supervision of a qualified sonographer or sonologist.

Requirements of the sonographer

A sonographer requires a wide general knowledge in:

- Human anatomy, embryology, physiology and pathology and a detailed knowledge of the anatomical regions in which he/she specialises. In particular, it is a necessity to have a three dimensional conceptual understanding of sonographic anatomical appearances, normal variations and pathological processes, in order to develop differential diagnoses.
- The physical principles of diagnostic ultrasound, including how the images are formed and recorded, and the associated artefacts which can be encountered.

The final diagnosis and writing of the report are the responsibility of the medical practitioner.

Responsibilities of the sonographer

Sonographers are required to:

- understand medical practice and terminology to allow for professional communication with the supervising medical practitioner, referring medical practitioner and colleagues;
- extend the examination to other areas as may be indicated by the findings during the examination;
- understand nursing procedures for the patients examined, and the procedures for medical emergencies, infection control and interventional techniques;
- assist in the education of student sonographers, medical practitioners and practitioners with an interest in diagnostic ultrasound;
- monitor equipment to ensure it is functioning properly, and evaluate new equipment;
- understand the principles of safety of ultrasound, including possible bioeffects and biohazards, and the implications regarding safe use of the equipment;
- appreciate and implement the principles of research;
- undertake continuing education to ensure maintenance of skills and the ability to adopt newly developed techniques in medical ultrasound;
- have excellent communication skills necessary to conduct the examination in a caring and professional manner; and
- maintain their professional standing through membership of an appropriate professional Society or Association.

Conclusion

By the nature of ultrasound examinations sonographers, compared with other imaging technologists, are accorded a high level of autonomy and responsibility in obtaining accurate diagnostic information from the ultrasound examination.

It is therefore particularly important that those involved in the diagnostic ultrasound process are cognisant of the requirements and responsibilities of sonographers described in this document.

Refer to *ASUM Policy on Diagnostic Ultrasound Services* (B1).



B7 Guidelines for the Operation of Vascular Ultrasound Practices

July 2007

Section 1 Documentation

1.1 Vascular Ultrasound Protocols

The vascular ultrasound protocols should be detailed and explicit detailing, on a step-by-step basis, the entire ultrasound examinations as performed in the practice. As most practices perform the examinations in a unique and individualised manner, it is important that the protocols are specific and describe the techniques actually used.

1.2 Diagnostic Criteria

- 1.2.1 A detailed description of the diagnostic criteria used for each examination should be maintained. This should accompany any charts, graphics or formulae used in the interpretation of the examination results. Specific references, including text or article, author, date, name and volume number of journal, or name of text and publisher should be provided.
- 1.2.2 A manual, containing diagnostic criteria that have been developed within the vascular practice or modified from standard published criteria, should be internally validated where possible. Internal validation is usually accomplished in the course of correlation and confirmation of test results.

1.3 Quality Assurance

Validation of vascular ultrasound against angiographic, surgical and/or internal validation is a critical part of quality assurance. Practices should maintain the following documentation:

- A statement detailing quality assurance measures and procedures should be maintained.
- The policy for the provision of Continuing Professional Development for all clinical staff.
- A policy for regular equipment maintenance.
- Policies and procedures to ensure patient safety.
- Policies and procedures on the retention, storage and destruction of patient information.

Section 2 Personnel

2.1 The Medical Director and Medical Staff

- 2.1.1 The Medical Director should hold an appropriate specialist qualification such as the FRACS (Vascular), FRANZCR, DDU or equivalent.

2.2 The Technical Director/Supervising Sonographer, Staff Sonographers and Student Sonographers

- 2.2.1 The Technical Director/Supervising Sonographer and Staff Sonographers must have appropriate ASAR or NZMRTB accreditation.
- 2.2.2 A Technical Director/Supervising Sonographer should be designated for the vascular practice, whose responsibilities include day to day operations of the practice, including maintenance and operation of the equipment.

2.3 Support Services (Nursing/Clerical/Other services)

The Medical Director must ensure that support services are appropriate and in the best interests of patient care.

2.4 Continuing Professional Development

All personnel should receive appropriate continuing professional development.

Section 3 Physical facilities

3.1 Examination Rooms

Examinations shall be performed in a setting providing reasonable patient comfort and privacy.

3.2 Interpretation Space

Adequate designated space shall be provided for the interpretation of the results and preparation of reports.

3.3 Storage Space

Adequate designated space shall be provided for the convenient storage of supplies, records and reports.

Section 4 Instrumentation

4.1 Equipment

Practices should ensure that their equipment is near to 'state of the art' as is reasonably possible.

4.2 Equipment Maintenance

A policy should exist for regular equipment maintenance to be performed on all equipment used for vascular ultrasound, including electrical safety checks, calibration and quality assurance.

4.3 Minimum Standard

The duplex Doppler ultrasound machine.

The duplex Doppler ultrasound machine is used to provide simultaneous or sequential real-time gray scale (B-mode) imaging of the vessel wall and plaque and analysis of the angle corrected Doppler frequency spectrum from a selected sample volume within the vessel lumen. As well as the essential characteristics of both B-mode imaging and duplex Doppler spectral analysis for quantification of blood flow velocities (or Doppler frequency shift), the ultrasound machine should have colour Doppler imaging. Colour Doppler provides a qualitative, simultaneous display of flow information superimposed on the real-time gray scale image. Required characteristics:

- Imaging frequencies as specified in anatomic regional sections.
- Range-gated Doppler with the ability to adjust the position and size of the range gate/sample volume.
- Provision for measurement and display of Doppler angle.
- Provision of visual and audible output of Doppler signal.
- Provision for hard copy or other form of recording.

Section 5 Patient safety

Practices should maintain specific written policies and procedures to ensure patient safety.

5.1 Incident Reports

A procedure must exist for the identification of patients who suffer untoward effects, or complications of studies performed. A permanent record of such incidents should be maintained.

5.2 Infection Control

Protocols must exist with respect to control of infectious diseases, transducer cleaning and protection of all personnel from the transmission of infectious diseases and blood-borne pathogens, in conformance with the specific policies of the Practice.

5.3 Emergency Procedures

Appropriate equipment, supplies and trained personnel should be available to deal with medical emergencies and critically ill patients.

5.4 Patient Confidentiality

All personnel will comply with professional principles of patient confidentiality at all times.

5.5 Ultrasound Safety

Applicants are referred to ASUM policies and statements regarding safety including the application of the ALARA principle (As Low As Reasonably Achievable) to the output power/intensity and examination time.

Section 6 Reporting practices

6.1 Reports

6.1.1 Diagnostic studies must be interpreted and reported by the Medical Director or by a qualified medical practitioner approved by the Medical Director. The report shall include the name of the medical practitioner performing the interpretation and be completed in a reasonable time after the study, as specified in the specific policies of the Practice.

6.1.2 The Sonographers' worksheet should be completed, in compliance with Health Insurance Commission stipulations. The name of the sonographer who performed the examination shall be included on the worksheet.

6.1.3 If preliminary reports are prepared, a policy should exist to include a mechanism for reconciling differences between preliminary and final reports, should this occur.

6.1.5 A policy for the provision of written and verbal reports to the referring clinician must exist. Adherence to this policy should be audited on a regular basis.

6.1.6 Retention of records must comply with the Medicare Benefits Schedule. Each Practice should have a policy defining how long patient records should be kept and when they must be destroyed.

6.2 Records

Details will be required of the system used in the practice to record the number and types of procedures performed and the method of hard copy and report storage.

The following policies were reaffirmed by ASUM Council in July 2007:

- D 14 Colour Duplex Doppler Ultrasound Extracranial Carotid Artery Disease
- D 15 Peripheral Arterial Ultrasound
- D 16 Intracranial Cerebrovascular Ultrasound
- D 17 Extracranial Cerebrovascular Ultrasound
- D 18 Penile Doppler Ultrasound
- D 19 Visceral Vascular Testing Using Ultrasound
- D 20 Peripheral Venous Ultrasound

Adjudication of ASM prizes and awards

Due to the generosity of ASUM corporate members a range of prizes and awards are offered for proffered presentations at the 2007 Annual Scientific Meeting. Prizes and awards are for specifically designated purposes as described on the published list of prizes and awards. Adjudication of the prizes and awards is undertaken by an Adjudication Panel under the auspices of the ASUM Education Committee.

In order to conduct the adjudication of prizes and awards in the most objective and equitable way, guidelines for adjudication and scoring sheets are used by the panel. The stated purpose of the prize or award is a major factor in determining the eligibility of contributions for a particular prize or award.

For the purpose of prizes and awards, contributions to the scientific program are broadly categorised into four groups:

1 Oral presentation of a descriptive clinical or literature review type

These may include a case study description, the description of a new technique or a literature based review of a particular topic.

2 Oral presentation of original research

This type of presentation will typically describe the methodology, results and conclusions of scientifically conducted, original research.

3 Poster presentation of a descriptive clinical or literature review type

These may include a case study description, the description of a new technique or a literature based review of a particular topic.

4 Poster presentation of original research

This type of presentation will typically describe the methodology, results and conclusions of scientifically conducted, original research.

Eligibility for particular prizes and awards is based on the nature of the presentation, professional category of the presenter and other criteria as described in the relevant prize or award description. In submitting a presentation for consideration for prizes and awards, contributors are advised to read carefully the following list of prizes and awards, and their descriptors, so as to determine the eligibility of contributions for a particular award.

Best Sonographer Research Presentation Award. Value \$A2000. Sponsored by Philips Medical Systems Australasia Pty Ltd

To be awarded for the best proffered research paper by a sonographer.

Best Research Presentation Award. Value \$A1500 Sponsored by Siemens Ltd – Medical Solutions

To be awarded for the best proffered research paper.

Anthony Tynan Best Clinical Presentation Award Value \$A1000 Sponsored by Siemens Ltd – Medical Solutions

To be awarded for the best clinical presentation proffered as a paper or poster.

Best Poster Award. Value \$A500 and a free registration for the presenting author to the next ASUM ASM. Sponsored by ASUM

To be awarded for the best poster.



Adjudication Guidelines for Oral Presentations

Presenter:

Title of Presentation:

Category of presentation:

- Descriptive clinical Literature review Original research

		POOR	CREDITABLE	OUTSTANDING		
ABSTRACT	Correctly portrays the presentation, demonstrates the relevance of the topic and creates interest	1	2	3	4	5
INTRODUCTION	Acknowledges Chair and audience. Describes the contextual relevance of the topic. Aims / hypothesis / purpose clearly stated.	1	2	3	4	5
CONTENT	Well developed description of topic / case.	1	2	3	4	5
	Relates topic / issues to local context and conditions.	1	2	3	4	5
	Integrates own thought and refers to other work on the topic.	2	4	6	8	10
	Describes the problem / issue / technique in detail.	2	4	6	8	10
	Discussion relates to, and is supported by relevant literature.	2	4	6	8	10
	Literature is appropriate and current.	1	2	3	4	5
	Comprehensive coverage.	1	2	3	4	5
CONCLUSION	Summarises major points / findings. Outlines recommendations for future work.	1	2	3	4	5
PRESENTATION	Audiovisual well sequenced and relevant to the presentation with appropriate image quality.	1	2	3	4	5
	Presentation well sequenced. Clear and audible presentation Holds audience interest.	1	2	3	4	5
ORIGINALITY	Original thought is evident in the selection of the topic.	1	2	3	4	5
	The methodology is appropriate and shows evidence of originality in its design.	2	4	6	8	10
VALUE	The topic is relevant and beneficial to the profession.	2	4	6	8	10
IF MORE THAN 2 MINUTES OVERTIME DEDUCT 50 POINTS					SCORE	/100

Adjudication Guidelines for Poster Presentations

Presenter:

Title of Presentation:

Category of presentation:

- Descriptive clinical Literature review Original research

		POOR	CREDITABLE	OUTSTANDING		
ABSTRACT	Correctly portrays the presentation, demonstrates the relevance of the topic and creates interest.	1	2	3	4	5
INTRODUCTION	Describes the contextual relevance of the topic. Aims / hypothesis / purpose clearly stated.	1	2	3	4	5
CONTENT	Well developed description of topic / case.	1	2	3	4	5
	Relates topic / issues to local context and conditions.	1	2	3	4	5
	Integrates own thought and refers to other work on the topic.	2	4	6	8	10
	Describes the problem / issue / technique in detail.	2	4	6	8	10
	Discussion relates to, and is supported by relevant literature.	2	4	6	8	10
	Literature is appropriate and current.	1	2	3	4	5
	Comprehensive coverage.	1	2	3	4	5
CONCLUSION	Summarises major points / findings. Outlines recommendations for future work.	1	2	3	4	5
DESIGN	Logical and easy to follow. Information presented concisely.	1	2	3	4	5
	Text is eye catching and easily viewed. Important points are well illustrated.	1	2	3	4	5
ORIGINALITY	Original thought is evident in the selection of the topic.	1	2	3	4	5
	The methodology is appropriate and shows evidence of originality in its design.	2	4	6	8	10
VALUE	The topic is relevant and beneficial to the profession.	2	4	6	8	10
					SCORE	/100

Fung Yee Chan 1955–2007

**Professor in Maternal Fetal Medicine, FRANZCOG, FHKCOG, FHKAM, FRCOG, DDU, CMFM, MD
Director of Maternal Fetal Medicine, Mater Mothers' Hospital, Brisbane**

Professor Fung Yee Chan died unexpectedly on 30th May 2007.

Fung Yee was a graduate of the University of Hong Kong. She received most of her specialist training in Hong Kong, including one year as a Commonwealth Scholar in Oxford in 1984. She was a Fellow of the Hong Kong, British, and Australian & New Zealand College of Obstetricians and Gynaecologists.

She and her family migrated to Australia in 1993. She completed the Certificate of Maternal Fetal Medicine of the RANZCOG in 1995 and was the first Queensland obstetrician to receive this sub-specialist certificate, and one of only 12 in Australia at that time. In the same year, she was awarded a Doctor of Medicine from the University of Hong Kong. She was the founding Director of Centre for Maternal Fetal Medicine at the Mater Mothers' Hospital, and held a conjoint appointment as Professor and Senior Specialist in Maternal Fetal Medicine at the University of Queensland, Mater Mothers' Hospital.

Prof Chan's interests covered all aspects of antenatal screening, diagnosis, and therapy. Recognising the difficulties in providing tertiary services poised by the vast size of Australia, her team successfully pioneered the use of real-time tele-ultrasound to provide sub-specialist expertise to regional centres in Queensland. She had many publications to her name, received several National awards, and was invited to scientific meetings locally and overseas to present this work. She spoke at many ASUM and ASA meetings and was a strong supporter and educator of medical ultrasound particularly in the field of obstetrics.

Her team's telemedicine expertise enabled a tele-link to a world-renowned fetal therapy centre in Florida (USA). This assisted in the successful introduction of fetal endoscopic surgery to Australia. The Mater team has now performed the largest number of fetoscopic laser surgeries for severe twin-to-twin transfusion syndrome in the Asia Pacific, with results matching the best centres around the

world. The team she established will continue to offer this essential service.

Fung Yee was also a great educator. She had a joint position between the Mater and the University of Queensland. She taught on a formal and informal basis to fellows, obstetric registrars, sonographers and medical students. She had a high level of clinical skills and was able to teach all who worked with her methods to improve their technical skills and research. She constantly supported her staff to improve their own skills and knowledge and was keen to learn from them too. She certainly had great respect for sonographers and their profession.

Fung Yee was, more importantly, a good caring person and doctor. She was loved by her patients and was able to speak to them in a way that they found easy to understand. She genuinely cared about their welfare and that of their children. Many patients visited our department to let her know how they were well after Fung Yee's medical care of them had finished. We have been inundated with calls from patients



since her death.

Fung Yee valued input from all members of her team, which included other specialists and sub-specialists, fellows, sonographers, midwives and administration staff, to name just a few. Our department will continue to operate as a team. We will continue to offer a high quality ultrasound and maternal fetal medicine service. She was a key member of the team and will be greatly missed but the team spirit she created will prevail.

Words can't describe the pain and loss we all feel. We will miss the familiar click of her heels in our corridors and the dangling of her keys around her neck. But she left us an important legacy, we must keep her caring purpose and vision long into the future to continue her work in the way she would have wanted.

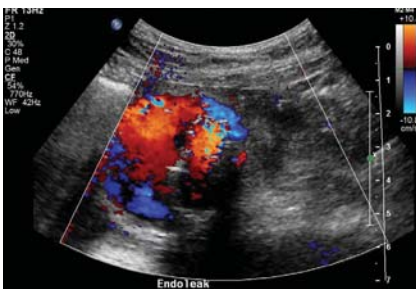
Alison Lee-Tannock



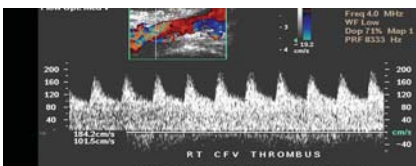
ASUM member wins her second prestigious award



Kathryn Busch and Prof John P Harris, Head, Department of Surgery, the University of Sydney.



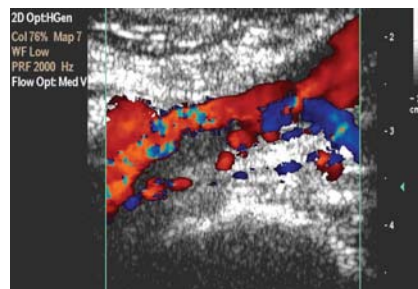
A large endoleak detected within the aneurysm sac that only became apparent when the patient was in the right lateral decubitus position. Other modalities failed to demonstrate an endoleak on this patient.



Spectral Doppler display of arterial flow within CFV thrombus.

Kathryn Busch, Technical Director at Camperdown Vascular Laboratory, Sydney, was awarded the 2007 Excellence in Oral Clinical Presentation Award for her presentation at the 2007 Society for Vascular Ultrasound (SVU) Annual Conference in Baltimore, MD, in June this year.

This is the second time in two years that Mrs Busch has taken out an award at the SVU Annual Conference. The SVU selected Mrs Busch's presentation from all those presented for her 'excellent clinical presentation' *Ultrasound detection of intermittent and position dependent endoleaks: evidence for a novel mechanism of AAA*



Longitudinal colour duplex image of arterial neovascularisation within a thrombosed CFV and perivenous tissue.

sac growth after endovascular repair. The presentation described a subset of patients whose aneurysms continue to expand following insertion of endoluminal grafts. Generally, aneurysm sac expansion following endograft placement indicates a possible complication, most commonly an endoleak. On occasion, no leak can be detected, which is regarded as 'endotension'.

By changing the patient position during an ultrasound examination it was found that endoleaks can be unveiled which are not detected using other modalities. This finding can prevent possible rupture of AAA by identifying and locating occult endoleaks enabling timely intervention.

In 2006, Mrs Busch was awarded the DE Strandness, MD, Scientific Award for the Outstanding Oral Presentation of Scientific Research in Vascular Technology for her scientific paper *High resolution duplex ultrasound imaging*

proves a high incidence of an arterial neovascularisation process associated with venous thrombosis. This award was established in 1987 in honor of Dr Strandness and is awarded annually to a SVU member who is the primary author and presenter of a scientific paper selected for presentation at the SVU Annual Conference. Its purpose is to recognise outstanding scientific research in vascular technology.

Her 2006 presentation described the existence of a process whereby arterial neovascularisation can be detected, using colour duplex ultrasound, within venous thrombus, the vein wall and surrounding tissue following venous thrombosis. Recanalisation is generally considered to involve thrombus organisation and retraction followed by the resumption of venous flow. The study demonstrated that the occurrence of arterial neovascularisation is part of the normal recanalisation process.

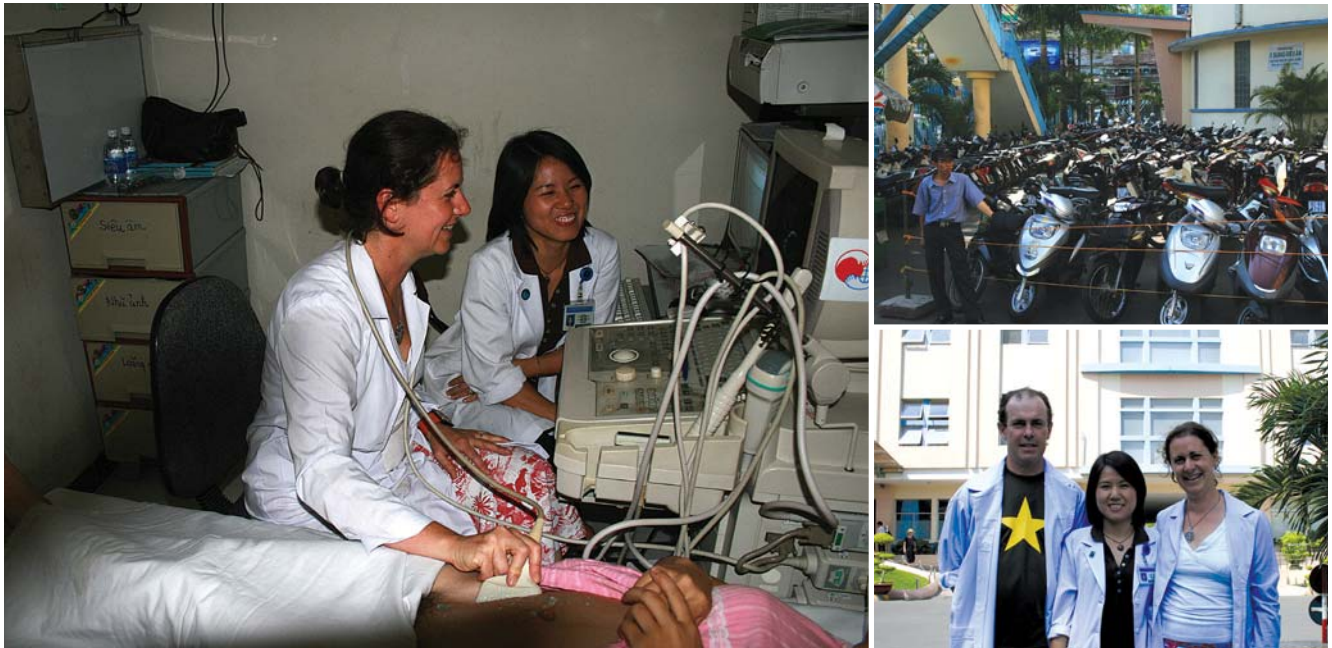Mrs Busch began training in vascular ultrasound in 1995 and was awarded the DMU (Vascular) by ASUM Council in February 1999. She is currently employed at Camperdown Vascular Laboratory and works in close association with the RPA Hospital Ultrasound Laboratory and the Department of Vascular Surgery.

When asked about her achievement she said: 'It was a great experience and a privilege to represent the team at Camperdown and RPAH at the 30th SVU anniversary meeting. I was blown away to hear that I had received such a prestigious award as a follow-up to the Strandness Award last year. It is good for the status of vascular sonography in Australia that we are able to present our research in major international meetings.'

Kathryn Busch unassumingly attributes her success to the excellent teachers she has had the privilege to work with over the years, from Vicki Grayndler in 1995 down the south coast to Jeni Kidd, the previous Technical Director at Camperdown, 'a great educator and mentor'.

Mrs Busch also thanked her sonographer colleagues for their amazing encouragement, particularly Virginia Makeham, Alison Burnett and Judith Doyle, and Prof John Harris and Prof Geoffrey White for their wisdom, encouragement and patience. Finally, she wishes to acknowledge Philips for their continued support.

Scanning at Tu Du Hospital Saigon



Clockwise: Dr Lanzarone and Dr Nguyen at Tu Du's ultrasound facility; The 'car' park at the hospital; Drs Lanzarone, Nguyen and Branley.

Sitting in front of my computer today, the memories of Saigon are still fresh, having just returned from a visit to Tu Du Hospital for Women a few days ago.

I was invited to spend a few weeks teaching the medical staff how to perform chorionic villus sampling (CVS) to compliment their successful implementation of first trimester combined nuchal translucency screening last year. ASUM very kindly provided me with financial assistance from the ASUM Vietnam Scholarship fund for the trip.

From the outside, Tu Du Hospital is smaller than most teaching hospitals in Sydney but it provides obstetric, gynaecological and breast surgery services to some four million Saigon women and many more who live in the provinces of South Vietnam. Forty-five thousand deliveries are performed in Tu Du Hospital every year and, accordingly, the numbers of ultrasounds performed each day is mind-boggling. The waiting room for nuchal and morphology scanning is the size of a basketball court and from before 7 am until evening has people hanging from the rafters, squatting on steps and crowding corridors. Being an open space, all inside are constantly blasted with the shrill of Saigon traffic and stifling heat and humidity. Adjacent are three scanning rooms, no less crowded with medical staff, medical observers, students,

Valeria Lanzarone writes on her experience of Saigon's busy Tu Du Women's Hospital

nursing staff and waiting patients lined up on chairs along one wall. The system needs to be quick and efficient but remains 'exac' as Dr Nguyen, the director of the unit, described it to me – meaning that although a morphology scan is done in 15 minutes, the expected standard is high.

Indeed, during my visit I observed a very high standard of scanning skill and well thought out protocols. Standard views which would be expected of these scans in an Australian setting were generally covered, with several additional features such as ear length and corpus callosum routinely examined. The efficiency of the system is permitted in part because manpower (or womanpower) is cheap. Nursing staff is used extensively to organise and direct the patients and to enter data and capture images to a locally-designed DICOM and reporting system. The reports follow hot off the press as quickly as the next patients appear. Scanning Vietnamese women, it has to be said, is a sonographer's dream; almost always very slim; usually 24–26 weeks when morphology examinations are done, and rarely demanding.

Those performing the scans are not expected to entertain or converse with the patient and do not break to counsel the patient in the event of an abnormality. Instead, this task falls to a clinician also in the room as an observer. I'm not likely to forget the scene of a patient being scanned and discussed, five others waiting their turn, a nurse generating a report, organising a DVD and printing a 3D memento (at a cost), and a woman being counselled, in earshot of those waiting at a desk squeezed into a corner, in a room no bigger than the average scanning room.

I was a visitor to the unit over the course of two weeks and was amazed by the volume of pathology presented to me for comment. It ranged from mild renal pathology to several severe skeletal dysplasias, florid trisomy 13 and 18, possible triploidy, complex cardiac abnormalities and many, many facial clefts and cases of fetal hydrops and ascites. In one afternoon I saw more cases than I routinely see in one year in Australia.

Often, the decision to be made is relatively black and white, i.e. whether to advise termination or follow the pregnancy and anticipate postnatal management. Although the advice is not always heeded, most Vietnamese women appeared relatively accepting of medical direction. There were times, however, when the contrary body





Plenty Tu Du, the hospital waiting room.

language was very familiar and made up for my lack of Vietnamese. I recall an afternoon when a 42-year-old woman carrying a baby with multiple abnormalities chose to continue with the pregnancy, knowing that aneuploidy was very likely, contrasted later by a young couple with a baby with a unilateral cleft lip who were determined to obtain a termination.

The director of the ultrasound unit at Tu Du Hospital is Dr Nguyen, a diminutive woman in her thirties, known to some as the 'princess' of the hospital because of her good looks and connections with the Nguyen Dynasty, the royal family of Vietnam until 1945.

Her easy grace and charm belie an unusual vigor and determination to bring her unit up to international standards. As the youngest director of a department at Tu Du Hospital, she is responsible for staffing and supervising 15 ultrasound machines and their operators, along with the ongoing education of her staff and auditing of the unit. She runs a tight ship and has several talented people working with her. They have overseen the introduction of several new developments, including the initiation to Vietnam of a very successful nuchal translucency screening program, the updating of ultrasound machines to newer models with 3D capabilities and formalisation of modern fetal morphology protocols.

She has fostered ties with ultrasound bodies in several overseas centres including Sydney, Paris and Angers and pursues further education

at a local level and overseas whenever possible. The result is an impressive level of productivity and competence in perinatal and gynaecological ultrasound. It was relatively easy to teach the basics of CVS to the more experienced workers in the unit. Already very competent at amniocentesis and skilled at ultrasound, this meant that mastering the slightly more complex technique of CVS was only a matter of time and practice.

The Vietnamese health system is intriguing. Vietnam shares many Asian attitudes about the value of commercialism. Surprisingly perhaps, in a communist country, health care in Vietnam is not free. All public hospital based treatments and investigations are paid for by the patients and a parallel private system of hospitals and clinics is growing rapidly. The costs for treatment in the government health system are relatively low and the standard of living for most Vietnamese is unexpectedly good, but this concept surprised me nevertheless. It also has implications for investigations done in the event of a fetal abnormality with the more pragmatic option of termination proceeded with without karyotyping or postmortem.

The visit I paid to the ward for abandoned children while there was an unexpectedly positive experience. Dr Thanh, the Director of the hospital, explained to me that one to two babies are born every day at Tu Du Hospital with malformations or syndromal conditions and many of these infants will die as a result of their problems. Some

of the survivors will be abandoned by their parents, often for financial reasons or lack of facilities to cope with these children in the less developed rural areas. Because of this, the hospital has made arrangements to care for these children. The wards are housed in a separate building and are impeccably, spotlessly clean and filled with bright toys and activity. Those caring for the children appear to enjoy the task and are gentle and genuinely affectionate. While some children are obviously severely retarded and bed ridden, many are mobile, bright and cheeky and the atmosphere is far from morbid. The unit has its own small school for the more able children. Dr Thanh explained that the government does not wholly subsidise the ward and that, instead, it is the donations of the hospital staff that keeps it to such a high standard. I discussed the concept of outside donations to the unit while I was there and was told that these would be gladly accepted. As such, I would urge any readers moved to make a financial contribution to these children's care to do so through ASUM which has agreed to pass the donations on to the hospital.

The hospital organised a national conference in perinatal medicine in May, with several Australian invited speakers, including Dr Henry Murray from Nepean Hospital whose visit was sponsored by ASUM.

It is evident that, while still regarded as a developing country, Vietnam is growing very rapidly and will soon parallel neighboring Asian countries such as Thailand, Singapore and Hong Kong for the level of its healthcare services. The small role ASUM is playing in assisting that progress is to be applauded and I thank them for facilitating my involvement.

I would like to extend my thanks to Paul Azcona of MISIR Australia and Cook Women's Health for their generous donations of medical supplies to Tu Du Hospital.

DONATIONS

Donations to Tu Du Hospital's unit for the care of abandoned children may be sent by cheque or money order payable to ASUM and marked Tu Du Hospital donation. All donations will be acknowledged.

2007 DDU Report

Enrolments in the 2007 Part 2 Diploma of Diagnostic Ultrasound Examination (DDU) have increased, compared to previous years.

Thirty-six candidates sat the Part I DDU. Twenty-four candidates sat the Part II, the highest number of candidates to ever sit Part II. This reflects favourably on the DDU qualification and confirms the accomplishment of the DDU Board of Examiners' (BoE) objective of making it a sought-after diploma, with relevance to all specialties.

In 2007, the Part I Examination was again conducted entirely by multi-choice questionnaire. The Part

II Examination's format remained the same as in previous years, however, the DDU BoE decided in 2006 that candidates who fail one particular segment may carry that part of the examination (either written or viva) for one year only. This brings the diploma more into line with other postgraduate qualification examinations.

I would like to congratulate our new DDU Secretariat, Dr Monica Pahuja, for arranging a successful viva examination held in Melbourne this year.

In future, we will see the DDU Viva Examination (except Cardiology) alternate between Sydney and Melbourne.

The Cardiology Viva Examination will continue to be held in Melbourne.

We welcome our first time DDU Viva Examiners: Dr Shawn Choong, Dr David Ferrar, Prof John Fletcher and Dr Geoff Schembri to Melbourne this year and also our new Cardiac Examiners Dr David Prior and Dr Peter Bergin. Our thanks are extended to the volunteers for invigilating the written exams and to Marie Cawood and her team for their efforts and time in supporting the DDU BoE.

Dr Chris Wriedt
Chair for DDU Board of Examiners

DDU 2007 pass candidates

DDU Part I

Jason Abbott
Alan Adno
John Bridgman
Andrew Cheung
Kim Mae Karin Chia
Sophia Chuang
Anthony Cross
Michael Dinh

Alison Fung
Christine Lai
Anna Lee
Regent Lee
Geoffrey Lee
Kong Foong Liew
Seshu Mandapati
Ritu Mogra
Roshini Nayyar
Rosemary Reid
Gregory Robinson
Renuka Sekar

Yasmin Tan
Dennis Wang

DDU Part II

Chuong Bui
Arvind Deshpande
Stephen Dunjey
Alexandra Ivancevic
Jacqueline Keene
Alka Kothari
Patricia Lai
Kristy Milward

Karen Mizia
Deirdre Percy
James Rippey
Nasser Shehata
Kate Stone
Gregory Sweetman
Raymond Sy
Alec Welsh
Hong Soo Wong

EDUCATION FOR THE MEDICAL PROFESSION SINCE 1985

HOME STUDY COURSES IN ALL ASPECTS OF DIAGNOSTIC MEDICAL ULTRASOUND INCLUDING:

BREAST, MUSCULOSKELETAL, ABDOMEN, OBSTETRICS, GYNAECOLOGY, ECHOCADIOGRAPHY, NEUROSONOLOGY AND VASCULAR

VISIT OUR WEBSITE:

WWW.BURWIN.COM



EXPAND YOUR HORIZONS

Australia • Middle East • UK



ChoiceOne are a leading Australian Medical Imaging Agency offering you amazing world-wide work options. Thanks to over 15 years international medical recruitment experience we can put you in touch with opportunities in **Australia**, the **United Kingdom**, **Saudi Arabia** and the **UAE**.

Talk to us now and let ChoiceOne send you packing.

1300 655 060 (Australia wide)

email: international@choiceone.com.au

262 St Georges Terrace Perth Australia 6000

Fax +61 8 9215 3885 www.choiceone.com.au

ChoiceOne
Meditemp



Why do we need a CCPU?



Dr Caroline Hong, Dr Anthony Joseph and Dr Glenn McNally

The concept of certifying physicians and surgeons was first floated by ASUM and ACEM in 2002 and the ASUM Council introduced a Certificate in Clinician Performed Ultrasound (CCPU) in 2003.

Initially, the CCPU was slow to develop but in 2006 the move to certify non-specialist medical practitioners who use ultrasound at the point of care in their daily practice started to gather momentum. Senior ASUM members, obstetrician gynaecologists, emergency physicians and surgeons began to formulate the CCPU curricula and the speciality certification programs. For some time, these doctors have been using focused ultrasound examinations in the clinical assessment of trauma patients and in procedures such as central line placement without undergoing the rigorous and relatively lengthy process of obtaining the Diploma in Diagnostic Ultrasound (DDU).

The clinicians and ASUM recognised that there was a need to standardise the learning process for the development of the cognitive and practical skills required for point-of-care ultrasound and establish standards of practice, hence the development of the CCPU curricula. These curricula provide pathways for non-specialist doctors to obtain an initial exposure to the practical theory of ultrasound and a framework for the development of the skills necessary for the practical application of point-of-care ultrasound. The CCPU is not intended to provide a shortcut to the DDU, although some of the clinicians may wish to undertake further study in order to obtain the DDU after the initial exposure gained during the CCPU. The DDU is and will remain the premier diagnostic

ultrasound tool used by specialist sonologists.

The CCPU has been developed in a modular format which is readily available on the ASUM website. Emergency physicians, surgeons, and obstetricians and gynaecologists can commence with a basic on-line physics module and an introductory practical workshop in, for example in Emergency Medicine and Surgical Practice, the use of the

Focused Assessment with

Sonography for Trauma (FAST) examination and the diagnosis of Acute Abdominal Aortic Aneurysm (AAA); obstetric gynaecological clinicians complete a basic obstetrics and gynaecology module. All CCPU candidates are then required to obtain a predetermined number of studies in the clinical setting and to validate their results by another study, or by a radiologist or a sonologist.

In Emergency, the use of point-of-care ultrasound to diagnose acute intra-abdominal or pericardial haemorrhage and/or an acutely expanding AAA is now a standard of care in most Australasian emergency departments staffed by fellows of the Australasian College for Emergency Medicine, as well as trainees and Fellows of the Royal Australasian College of Surgeons. Other developing uses of point-of-care ultrasound include the ruling in, or out, of an intrauterine pregnancy associated with first trimester bleeding, the insertion of central venous catheters in real time and the diagnosis of acute deep vein thrombosis (DVT) in proximal femoral and popliteal veins.

As most radiology sonologists and sonographers with either DDU or DMU qualifications are usually only available on-site during business hours and on-call after hours, the need for focused point-of-care ultrasound in the acute setting has developed. The CCPU has not been developed to replace the more comprehensive medical imaging department ultrasound examinations, but to answer important clinical questions usually with a positive or negative response in an acute or life-threatening situation, such as trauma or vaginal bleeding.

Currently, there are established curricula for obstetrics and gynaecology, emergency, surgical practice, neonatology and rheumatology.

CCPU Basic Modules have been developed for:

- FAST/AAA examinations;
- DVT/central line insertion;
- First trimester bleeding;
- Shoulder and knee examinations;
- Neonatal echocardiography and ultrasound of the neonatal brain; and
- 1st trimester ultrasound; 2nd and 3rd trimester biometry; placenta; amniotic fluid; normal pelvis, endometrial thickness.

CCPU Advanced Modules have been developed for:

- Acute pelvic pathology;
- Acute gynae and first trimester bleeding;
- DVT and vascular assess;
- Abnormal bleeding: initial screening;
- Ovarian pathology: initial screening;
- Thyroid;
- Breast;
- Principles of screening for chromosomal abnormality;
- Right upper quadrant (RUQ);
- Acute scrotum;
- Ocular;
- Kidneys and bladder;
- Advanced neonatal echocardiography;
- Structural neonatal brain abnormalities and the asphyxiated infant;
- Advanced upper limb;
- Advanced lower limb; and
- Shoulder and knee examinations.

CCPU curricula are being prepared for nephrological and sport and exercise medicine ultrasound.

ASUM is the obvious body to develop and control the CCPU and this qualification should be seen not as a threat to formal radiology department sonography but rather as complimentary in meeting an, until now, unfulfilled gap in clinical care.

Dr Tony Joseph
Royal North Shore Hospital

CORRECTION

Dr Anthony Joseph was incorrectly named Dr Andrew Joseph in the last issue. *Ultrasound Bulletin* regrets the error which was made during the production process

ASUM CCPU Report

The Certificate in Clinician Performed Ultrasound (CCPU) program is currently open to fellows or registrars in the second or subsequent year of their training of the Australasian College for Emergency Medicine (ACEM), the Royal Australasian College of Surgeons (RACS) and the Royal Australian and New Zealand College of Obstetricians and Gynaecologists (RANZCOG). The ASUM CCPU Certification Board oversees the CCPU, with representatives appointed by ASUM, ACEM, RACS and RANZCOG.

2006/2007 has been a period of development and consolidation for the CCPU with Basic CCPU Module courses and Advanced Module courses for the CCPU (Emergency) and the CCPU (obstetrics and gynaecology) were conducted in Sydney and Melbourne.

ASUM Council awards the CCPU in the disciplines of emergency medicine, obstetrics and gynaecology and surgical practice.

The first CCPU was issued this year to Dr Anthony Joseph in Emergency – Acute Pelvic. Speciality Panels for emergency, obstetrics and gynaecology, neonatology and surgical practice have been established to assist the CCPU Certification Board. Discussions are in progress with the College of Rheumatology, the Australasian College of Phlebology

Registered in CCPU

Speciality	Registered	Completed Physics	Completed a Basic Module	Completed an Advanced Module	CCPU Awarded
CCPU (Emergency)	32	20	15	8	1
CCPU (O&G)	23	14	15	2	–
CCPU (Surgical)	6	2	–	–	–
CCPU GP (O&G)	1	1	1	–	–
TOTAL	62	37	31	10	1

and the Australian and New Zealand Society of Nephrology to prepare appropriate ultrasound training curricula for their individual members. It is intended that we will be offering the CCPU in these areas from 2008.

Discussions are also currently being held with the Australian Defence Forces (ADF) with the view to formulating an appropriate curriculum for a certificate for ADF Medical Officers. This new certificate will be called the Certificate in Clinical Military Ultrasound (CCMU).

It is intended that Medical Officers, upon completion of their military service, may progress to the CCPU by completion of an Advanced Module in emergency, obstetrics and gynaecology or surgical practice and by fulfilling the

appropriate Advanced Module logbook requirements.

CCPU Certification Board

Glenn McNally (ASUM) Chair
 Andrew Ngu (ASUM)
 Anthony Joseph (ACEM Representative)
 Michael Hession (ASUM)
 Cheryl Bass (Representing the ASUM President, Emergency Panel Chair, Surgical Panel Chair)
 Monica Pahuja (ASUM, O&G Panel Chair, Neonatal Panel Chair)
 Peter Barry (RACS Representative)
 Peter Hugo (RANZCOG Representative)
 Kaye Griffiths AM (ASUM)

WA Ultrasound CPD Meeting

The WA ultrasound community was presented with a smorgasbord of presentations by invited interstate personalities Dr Cheryl Bass and Mr Chris Sykes, supported by an array of local speakers.

The meeting was held on the weekend of 30th June–1st July at Royal Perth Hospital. It was chaired by Mrs Natalie Colley, WA Branch Chair.

There were sessions in breast ultrasound, MSK, vascular, general and obstetrics and gynaecology

Registrants were given a break from the educational overload, with a dinner at The Old Swan Brewery, which overlooks the Swan River and Perth's CBD.

The WA Branch awarded Mrs Marilyn Zelesco and Mrs Elvie Haluszkiewicz for their dedication and contributions to ultrasound education for more than 15 years.

This very successful weekend was kindly supported by Toshiba, GE/HTCA, Philips and Siemens.

New intake at Vision College



Vision College in Kuala Lumpur welcomed a new intake of students for the DMU (Asia) course in June this year.

Brian Starkoff (second from right in back row) initiated the students in their first week, with lectures on the full DMU Physical Principle and Instrumentation syllabus. 'It was a pleasure to lecture to these students,' Brian Sarkoff reports, 'the students were up to the task, demonstrating high levels of enthusiasm and eagerness to learn.'



Corporate members

Australian Medical Couches

Marcus Egli
tel (03) 9376 0060
claudia@australianmedical
couches.com
www.australianmedical
couches.com

Bambach Saddle Seat Pty Ltd

Sue Johnston
tel (02) 9939 8325
sjohnston@bambach.com.au
www.bambach.com.au

Bristol-Myers Squibb Medical Imaging

Wayne Melville
tel (02) 9701 9108
mob 0409 985 011
wayne.melville@bms.com
www.bms.com

Central Data Networks P/L

Robert Zanier
tel 1300 722 632
mob 0407 069 307
info@cdn.com.au
www.cdnpacs.com

CR Kennedy

Graham Hines
tel (03) 9823 1515
gshines@crkennedy.com.au
www.crkennedy.com.au

Focus Medical Technologies

Laurence Heron
tel (02) 9209 4530
info@focusmedical.com.au
www.focusmedical.com.au

GE Healthcare

Stephanie Mason
tel (02) 9846 4000
stephanie.mason@ge.com
General Manager Kevin Potter
www.gemedicalsystems.com

Healthsite Recruitment Australia

Ian Stewart
tel (07) 5445 4604
ian.stewart@healthsite
recruitment.com
www.healthsite
recruitment.com

Inderlec Medical Systems Pty Ltd

Jeff Gibson
tel 1300 364 336
email jeff@inderlec.com.au
www.inderlec.com.au

Meditron Pty Ltd

Michael Fehrmann
tel (03) 9879 6200
info@meditron.com.au
www.meditron.com.au

Peninsular Vascular Diagnostics

Claire Johnston
tel (03) 9781 5001
pvdvic@austarmetro.com.au

Philips Medical Systems Australasia Pty Ltd

Kathryn Davis
tel (02) 9947 0158
kathryn.davis@philips.com
CEO Harry van Dyk
www.medical.philips.com

Queensland X-Ray

James Abbott
tel (07) 3343 9466
James.abbott@qldxray.
com.au
www.qldxray.com.au

Siemens Ltd – Medical Solutions

Nick Kapsimallis
tel (02) 9491 5863
nick.kapsimallis
@siemens.com
Marketing General Manager
Cameron Marcuccio
www.medical.siemens.com

Sonosite Australasia Pty Ltd

Matthew Tucker
tel 1300 663 516
matt.tucker@sonosite.com
www.sonosite.com

Symbion Imaging

Mark Mooney
tel (02) 9005 7702
mark.mooney@symbion
health.com
www.symbionhealth.com

Toshiba (Aust) Pty Ltd Medical Division

Louise Archer
tel (02) 9887 8041
larcher@toshiba-tap.com
General Manager Nick Swaan
www.toshiba.com.au

ASUM invites suppliers of
medical equipment,
services and consumables
to join the Society.
Call Dr Caroline Hong
tel +61 2 9438 2078 for
intormation.

New ASUM members

APRIL 2007

FULL (6)

Jayesh Gohil NSW
Krishna Kadappu NSW
Cushla King NZ
Ross O'Neil ACT
Bruce Schirmer NSW
Samantha Wong SA

ASSOCIATE (9)

Loida Baloco Vic
Yiing Fen Chong Vic
Debbie Edwards Qld
Joanne Gadd NSW
Adam Holmes Qld
Sarah Knox WA
Yean Mok Qld
Antoinette Schulz NSW
Kate Wilkinson Qld

CORRESPONDING (12)

Rasheed Ahamed Bin
Allapitchay Malaysia
Fong Mun Lum Malaysia
Wei Wei Ng Malaysia
Suan Lee Ong Malaysia
Siew Cheng Pang
Malaysia
James Shepherd USA
Linda Shepherd USA
R.Mohd Irwanshah Sule
Malaysia
Ban Nee Tan Malaysia
Wee Yin Wong Malaysia
Hoi Siang Yong Malaysia
Hua Mey Yong Malaysia

MAY 2007

FULL (11)

Sandra Cameron NZ
Katherine Fitzgerald NZ
Vivek Kulkarni Qld
Ashok Kumar WA

Roopa Lakhanpal NSW
Mikhail Mikhail Qld
Troy Morrison SA
Semone Rilstone SA
Karen Robertson NZ
Ka Man Siu NSW
Eric Williams WA

ASSOCIATE (9)

Matthew Bragg NSW
Vincent Ying-Chao Chan WA
Jillian Earle NZ
Irene Ho NSW
Jeremy Pallot NSW
Jade Rosen Vic
Máté Rudas NSW
Susan Stace NSW
Xia Yu Qld

JUNE 2007

FULL (9)

Kevin Gilbert NZ
Adam Hall Qld
Susan Kitto Qld
Lucy Liu NSW
Emma Parry NZ
Stephanie Sharp NZ
Kaye Swallow Qld
Hasan Titiz Qld
Bit Wong NSW

ASSOCIATE (5)

Paul Dundas Qld
Anthony Morris WA
Sheri Rae NSW
Vadim Smolianinov NZ
Wei Zheng NSW

AFFILIATE (4)

Kirsten Black NSW
Nicola Bryan Vic
Raiyomand Dalal NSW
Adrian Thomas Vic

MEMBERSHIP RENEWALS

Valued members who have not yet renewed their ASUM membership are reminded that we are now in the new financial year. As at 1st July 2007 your membership lapsed and you will not have access to the member-only area of our website for internet on-line payments.

Call the ASUM Secretariat to pay by telephone or for a renewal notice to be sent to you. Contact Katrina Latham or Marie Cawood tel (02) 9438 2078 or email katrina@asum.com.au or marie@asum.com.au

Subscription renewals due for payment

Medical / Scientific /	
Sonographer members	\$324.50 (incl. GST)
Associate members	\$253.00 (incl. GST)
Trainee members	\$253.00 (incl. GST)
Retired members	\$110.00 (incl. GST)
Corporate members	\$1210.00 (incl. GST)
Corresponding ordinary members	\$214.50
Corresponding associate members	\$165.00

DDU 2008 FEES

- Part I** \$A990.00 (incl. GST) Examination fee for ASUM members sitting in Australia
 - Part I** \$A900.00 (ex GST) Examination fee for ASUM members sitting in New Zealand
 - Part II** \$A1760.00 (incl. GST) Examination fee
 - Part II** \$A330.00 (incl. GST) Casebook fee
 - Part II** Candidates sitting exam for second time, viva and report writing portion only
 - Part II** \$A880.00 (incl. GST) Examination fee for viva and report writing portion of exam to approved candidates only
- Applicants must be a member of ASUM to sit the DDU exam-ination. Application forms for both the DDU exam and ASUM membership may be downloaded from the ASUM website at www.asum.com.au

DDU 2008 DATES

- Part I**
The Part I Examination will be held on Monday 12th May 2008. Application closing date is Monday 17th March 2008.
- Part II**
Casebooks for 2008 Part II DDU Examination must be submitted by Monday 14th Jan 2008 and accompanied by the prescribed fee of A\$330.00 for all participants.
- The Written Examination for Part II** will be held on Monday 12th May 2008. The Application closing date is Monday 17th March 2008.
- The Oral Exam for Cardiology** candidates only will be in MELBOURNE on Thursday 19th June 2008.
- The Oral Examination for Part II** candidates (excluding Cardiology) will be held in SYDNEY on Saturday 21st June 2008.

DMU 2008 KEY DATES

- Part I and Part II Application** Open 1st Dec 2007
- Part I and Part II Application** Close 31st Jan 2008
- Part I and Part II Late Application** Close 31st March 2008
- Application for Exemption** Close 31st March 2008
- DMU Preparation Course**
 Sydney – 26th March to 30th March 2008
- DMU Part I Written Examination** 26th July 2008
- DMU Part II Written Examination** 26th July 2008
- DMU Part II Oral Examination Period** Sept 2008
- DMU Part II Practical Examination Period** Aug 2008
- DMU Part I Supplementary Written Exam** 1st Nov 2008

2008 DMU EXAMINATION FEES

DMU Enrolment (once only fee) \$A326.00 + GST	\$A358.60
DMU Part I APP \$A326.00 + GST	\$A358.60
DMU Part I PHY \$A326.00 + GST	\$A358.60
DMU Part II Written \$A540.00 + GST	\$A594.00
DMU Part II Oral \$A540.00 + GST	\$A594.00
DMU Part II Practical \$A800.00 + GST	\$A880.00
Supplementary Examinations	
DMU Part I Suppl APP \$A326.00 + GST	\$A358.60
DMU Part I Suppl PHY \$A326.00 + GST	\$A358.60

2007

3rd–8th September 2007 IBUS – International Breast Ultrasound Course: Multimodality imaging and interventional techniques

Ferrara, Italy
 Contact Administrative Secretary tel +39 0532 762404
 fax +39 0532 767347 email convegna@unife.it or info@ibus.org
 website www.iuss.unife.it

13th–16th September 2007 4 days ASUM 2007 37th Annual Scientific Meeting

Cairns Convention Centre. Cairns North Queensland Australia
 Contact ASUM PO Box 943, Crows Nest NSW 1585 Australia
 tel +61 2 9438 2078 fax +61 2 9438 3686
 website www.asum.com.au for online registration

7th–11th October 2007 17th World Congress on Ultrasound in Obstetrics and Gynaecology

Venue Palazzo dei Congressi/Palazzo degli Affari Florence, Italy
 Contact www.isuog2007.com_congress@isuog.org
 tel +44 (0) 20 7471 9955 fax +44 (0) 20 7471 9959

3rd–7th October 2007 The Chicago International Breast Course

Co-sponsored by Northwestern Radiology and the University of Chicago. The Westin Chicago River North Chicago, USA
 Contact Anne Healy tel +1 312 695 0730 fax +1 312 695 5645
 email Anne.Healy@nmff.org
 website www.radiology.northwestern.edu/edu/cibc/index.cfm

12th–16th November 2007 AFSUMB 2007

Venue Bangkok
 email siwbs@mahidol.ac.th website www.afsumb2007.or

2008

26th–30th March 2008 ASUM Multidisciplinary Workshop

Sydney, Australia
 Contact ASUM PO Box 943, Crows Nest NSW 1585 Australia
 tel +61 2 9438 2078 fax +61 2 9438 3686
 website www.asum.com.au

26th July 2008 ASUM DMU Part I & Part II Written Examination Provisional

Venue as allocated. Candidates receive individual notification
 Contact DMU Coordinator
 tel +61 2 9438 2078 fax +61 2 9438 3686
 email dmu@asum.com.au

18th–21st September 2008 ASUM Annual Scientific Meeting Sky City Auckland Convention Centre, New Zealand

Contact ASUM PO Box 943, Crows Nest NSW 1585 Australia
 tel +61 2 9438 2078 fax +61 2 9438 3686
 website www.asum.com.au

2009

30th August–3rd September 2009 ASUM hosts WFUMB 2009 World Congress in Sydney

Sydney Convention and Exhibition Centre
 Contact Dr Caroline Hong
 ASUM CEO carolinehong@asum.com.au or asum@asum.com.au
 ASUM Head Office
 PO Box 943, Crows Nest NSW 1585 Australia
 websites www.asum.com.au and www.wfumb2009.com

For full listing see www.asum.com.au



Guidelines for authors

Authors are invited to submit papers for publication in the categories described below. Final responsibility for accepting material lies with the Editor, and the right is reserved to introduce changes necessary to ensure conformity with the editorial standards of the *Ultrasound Bulletin*.

Original research

Manuscripts will be subject to expert referee prior to acceptance for publication. Manuscripts will be accepted on the understanding that they are contributed solely to the *Ultrasound Bulletin*.

Quiz cases

A case study presented as a quiz, involving no more than three or four images and a paragraph briefly summarising the clinical history as it was known at the time. It will pose two or three questions, and a short explanation.

Case reports

Case reports are more substantial presentations resembling short scientific papers which illustrate new information, or a new or important aspect of established knowledge.

Review articles

Review articles are original papers, or articles reviewing significant areas in ultrasound and will normally be illustrated with relevant images and line drawings. Unless specifically commissioned by the Editor, articles will be subject to expert referee prior to acceptance for publication.

Forum articles

Members are invited to contribute short articles expressing their observations, opinions and ideas. Forum articles should not normally exceed 1000 words. They will not be refereed but will be subject to editorial approval.

Calendar items

Organisers of meetings and educational events relevant to medical ultrasound are invited to submit details for publication. Each listing must contain: activity title, dates, venue, organising body and contact details including name, address, telephone and facsimile numbers (where available) and email address (where available). Notices will not usually be accepted for courses run by commercial organisations.

Corporate news

Corporate members are invited to publish news about the company, including structural changes, staff movements and product developments. Each corporate member may submit one article of about 200 words annually. Logos, illustrations and tables cannot be published in this section.

Format

Manuscripts should be submitted in triplicate in print and on PC formatted diskette as MS Word documents.

Images must be supplied separately and not embedded. PowerPoint presentations are not accepted.

- Font size: maximum 12 pt, minimum 10 pt

- Double spacing for all pages

- Each manuscript should have the following:

Title page, abstract, text, references, tables, legends for illustrations.

- Title page should include the:

Title of manuscript, the full names of the authors listed in order of their contribution to the work, the department or practice from which the work originated, and their position.

Corresponding author's name, contact address, contact telephone number and facsimile number (where available) for correspondence.

- Abbreviations may be used after being first written in full with abbreviation in parentheses.

- References should be cited using the Vancouver style, numbered according to the sequence of citation in the text, and listed in numerical order in the bibliography. Examples of Vancouver style:

1 In-text citation Superscript. If at the end of a sentence the number(s) should be placed before the full stop or comma.

2 Journal article Britten J, Golding RH, Cooperberg PL. Sludge balls to gall stones. *J Ultrasound Med*

1984; 3: 81–84.

3 Book: Strunk W Jr, White EB. *The elements of style* (3rd ed.). New York: Macmillan, 1979.

4. Book section Kriegshauser JS, Carroll BA. The urinary tract. In: Rumack CM, Wilson SR, Charboneau JW, eds. *Diagnostic Ultrasound*. St Louis, 1991: 209–260.

Abstract

Manuscripts for feature articles and original research must include an abstract not exceeding 200 words, which describes the scope, major findings and principal conclusions. The abstract should be meaningful without reference to the main text.

Images

Images may be submitted as hard copy (in triplicate) or in digital format. Images sent must have all personal and hospital or practice identifiers removed. Do not embed images in text. Separate images are required for publication purposes.

A figure legend must be provided for each image. Hard copy images should be presented as glossy print or original film. Any labelling should be entered on the front of the glossy print using removable labels. Send one copy of illustrations without labelling as this can be added electronically prior to publication. On the back of the print include the author's name, figure number and a directional arrow indicating the top of the print.

Digitised graphics should be supplied as JPG or TIFF files on PC formatted 3.5" diskette or CD, which must be clearly labelled with the author's name and the names of the image files.

Copyright

Authors are required to provide assurance that they own all property rights to submitted manuscripts, and to transfer to ASUM the right to freely reproduce and distribute the manuscript.

2007 / 2008 ULTRASOUND BULLETIN PUBLICATION DATES

	Nov 07	Feb 08	May 08	Aug 08	Nov 08
Submission Deadline	10 Oct	10 Dec	31 Mar	30 June	29 Sep
Post Date	16 Nov	15 Feb	16 May	8 Aug	14 Nov